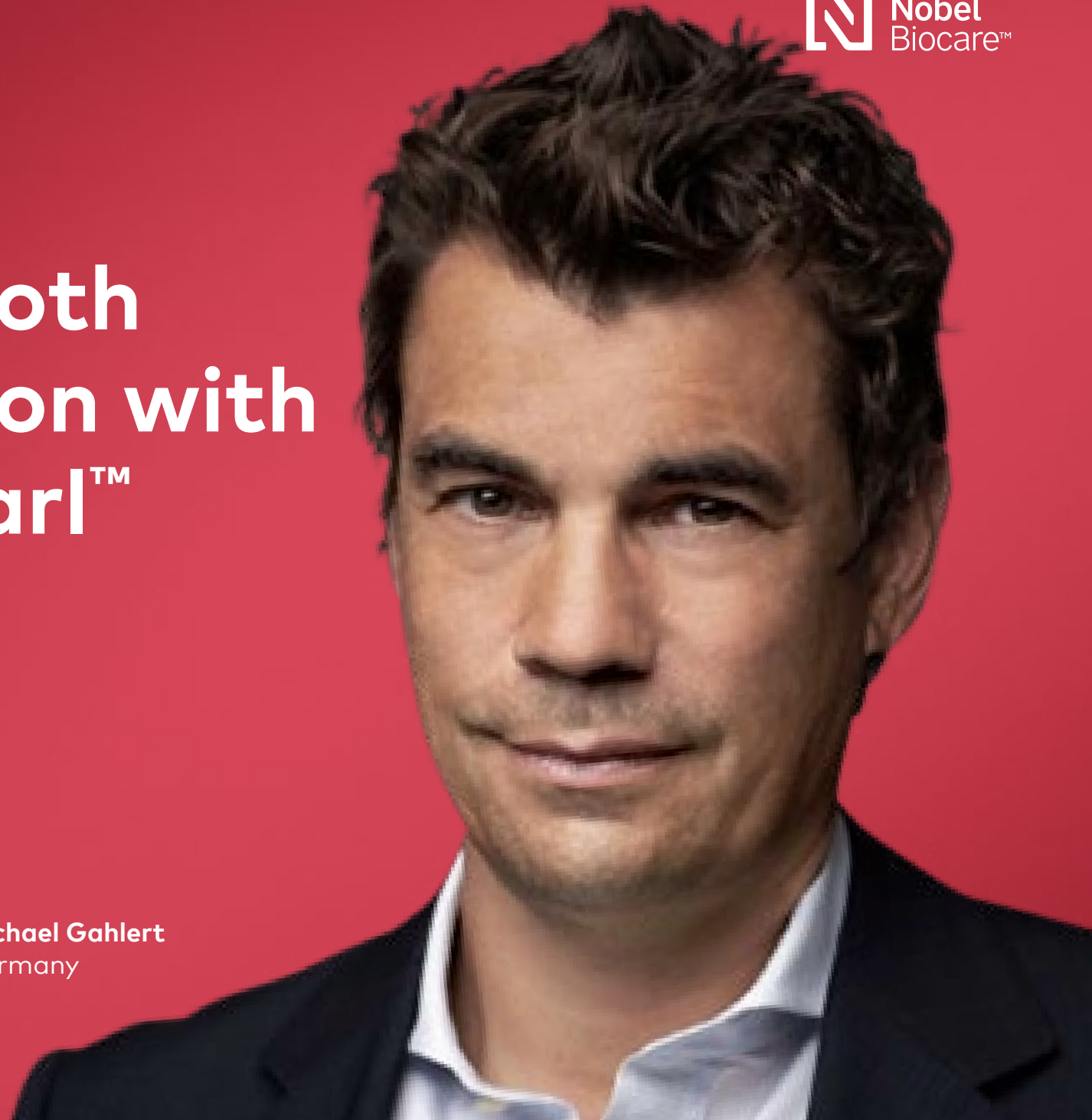

CLINICAL CASE



Single tooth restoration with NobelPearl™

Michael Gahlert
Germany





Michael Gahlert

Patient

Female, 42 years old, healthy

Clinical situation

Healthy oral conditions,
good bone quality
Anodontia tooth 35 and 45
(FDI Scheme)

Surgical solution

NobelPearl™ single implant

Restorative solution

Prefabricated ceramic
abutment retained by
VICARBO® Definitive Clinical
Screw. The full ceramic
crown was cemented with
Ketac™ Cem Glass ionomer
cement.

Surgery date(s)

07/08/2018 and 11/10/2018

Total treatment time

4 months

Tooth position

Tooth gap 25 (FDI Scheme)

"For me the most important attributes of NobelPearl ceramic implants are the unique carbon-fibre screw for effective abutment anchorage, strong alumina-toughened zirconia material, and the micro-rough surface for predictable osseointegration.

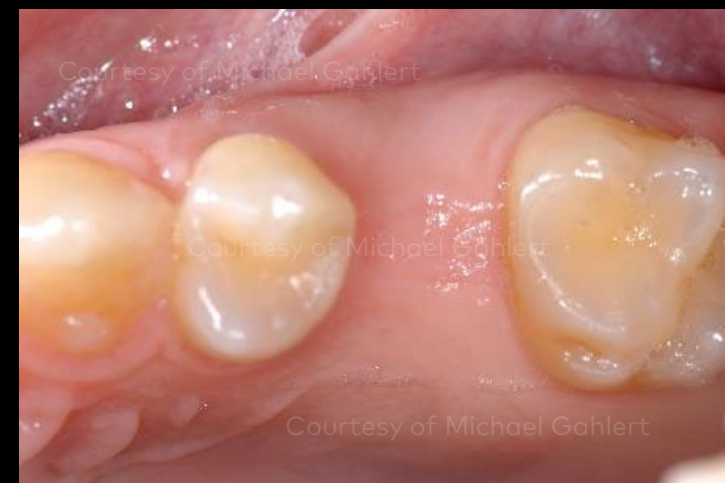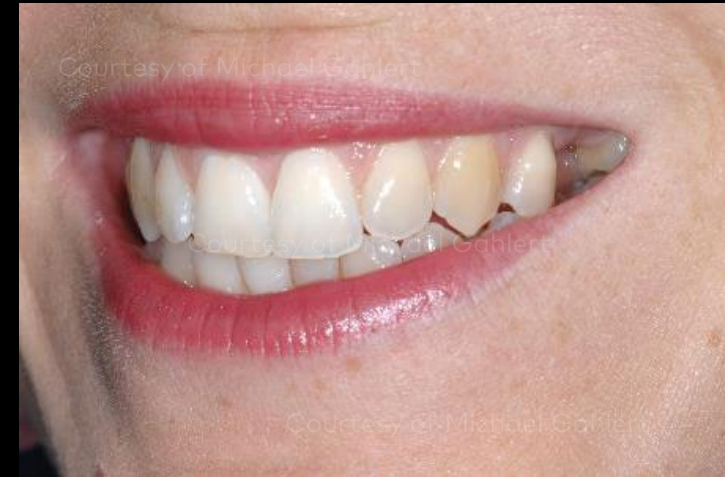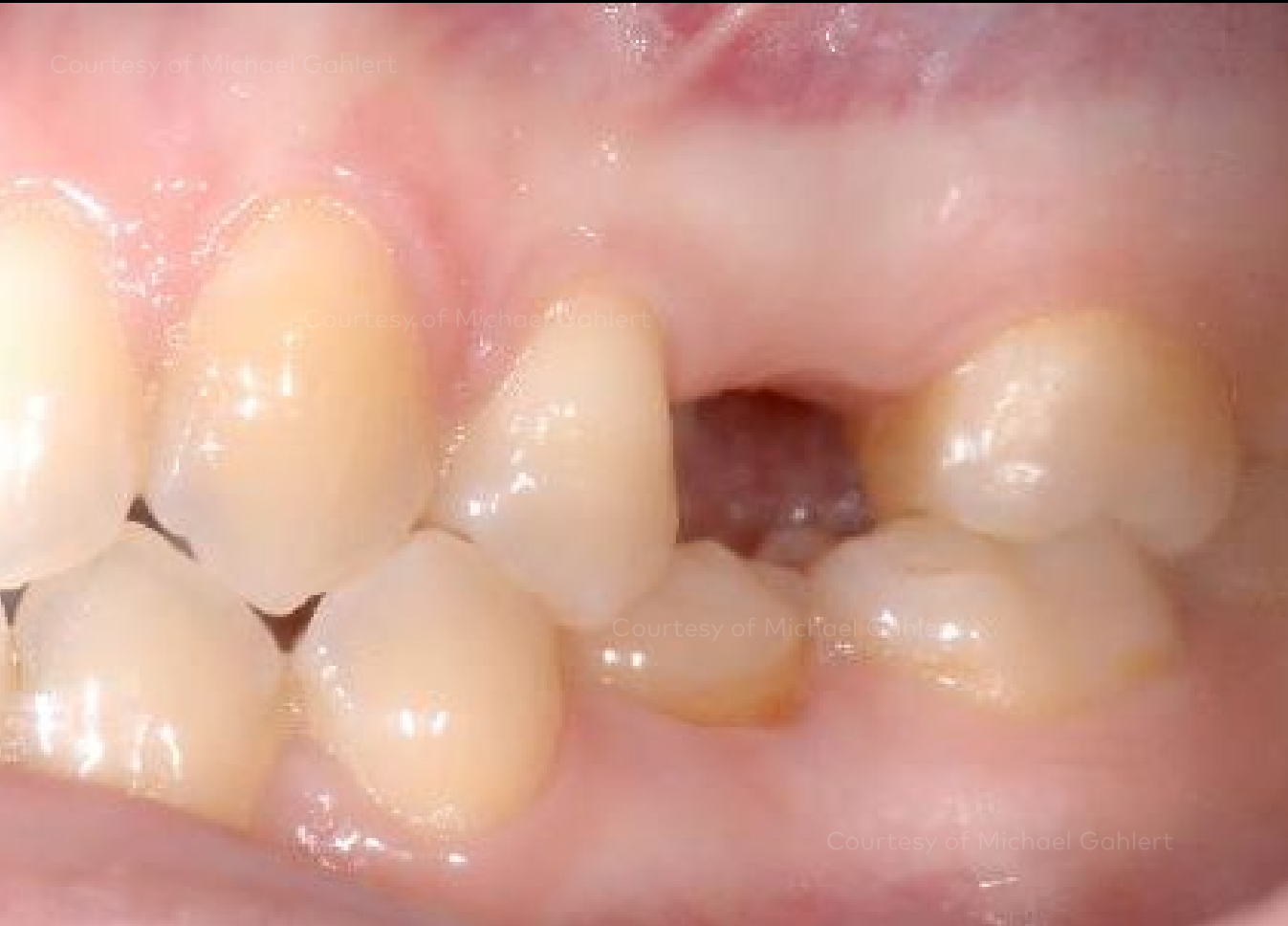Two-piece NobelPearl ceramic implants are the future metal-free alternative for established titanium implants!"

Initial clinical situation

Surgical procedure

Restorative procedure

Outcome



Healthy soft-tissue condition.
The persistent milk tooth 75 is visible under normal bite conditions.

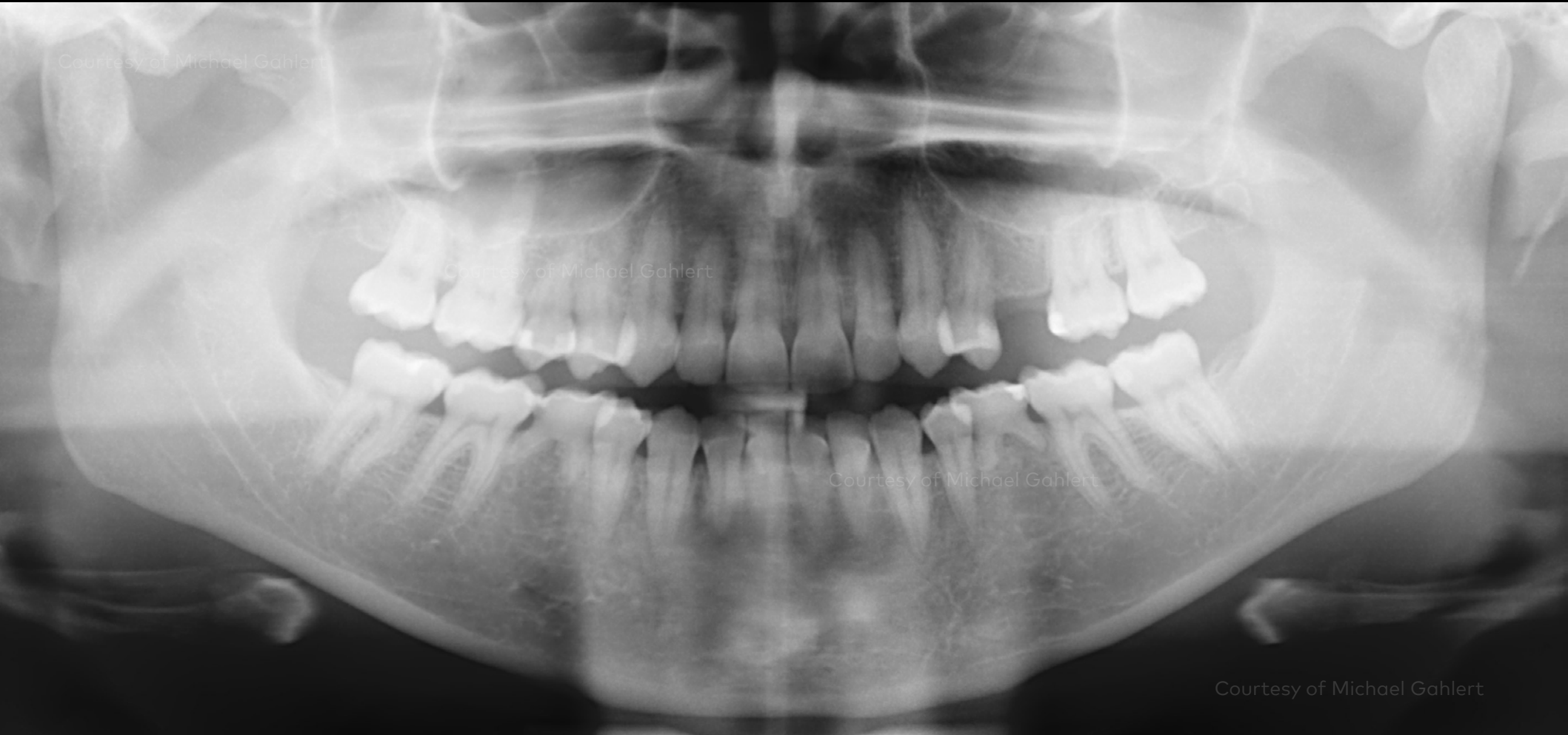Top. Lip line during laughing shows the tooth gap.
Bottom. Healthy soft-tissue conditions and
adequate bone for implantation.

Initial clinical situation

Surgical procedure

Restorative procedure

Outcome



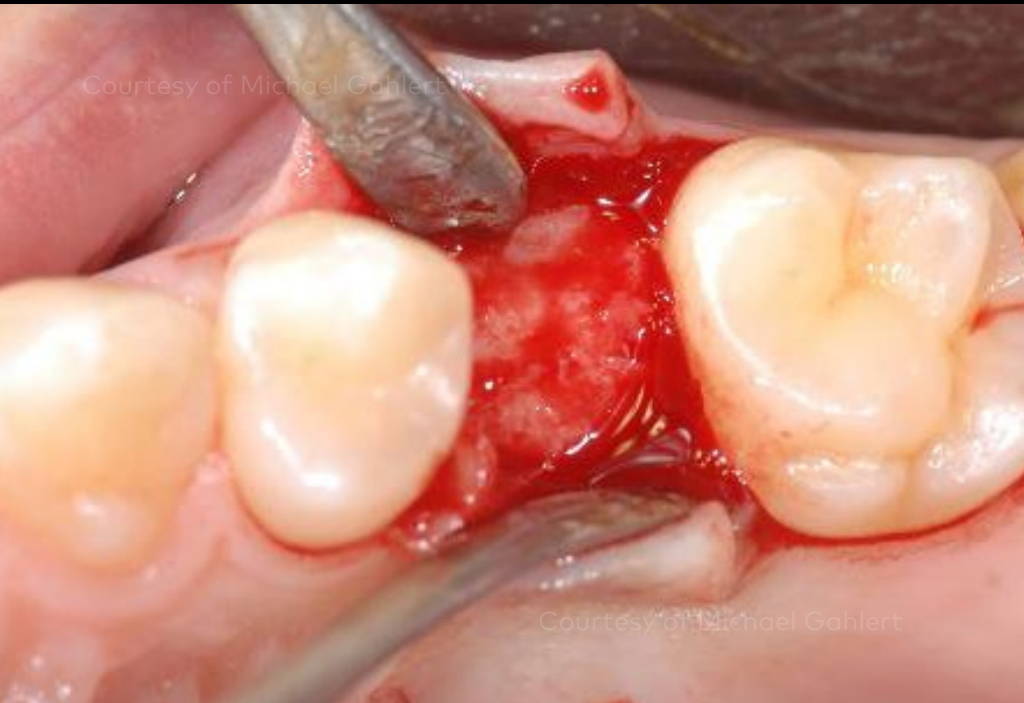Visible gap 25 and persistent milk teeth 75 and 85, but no other pathologic alterations in the orthopantomogram (OPG).

Initial clinical situation

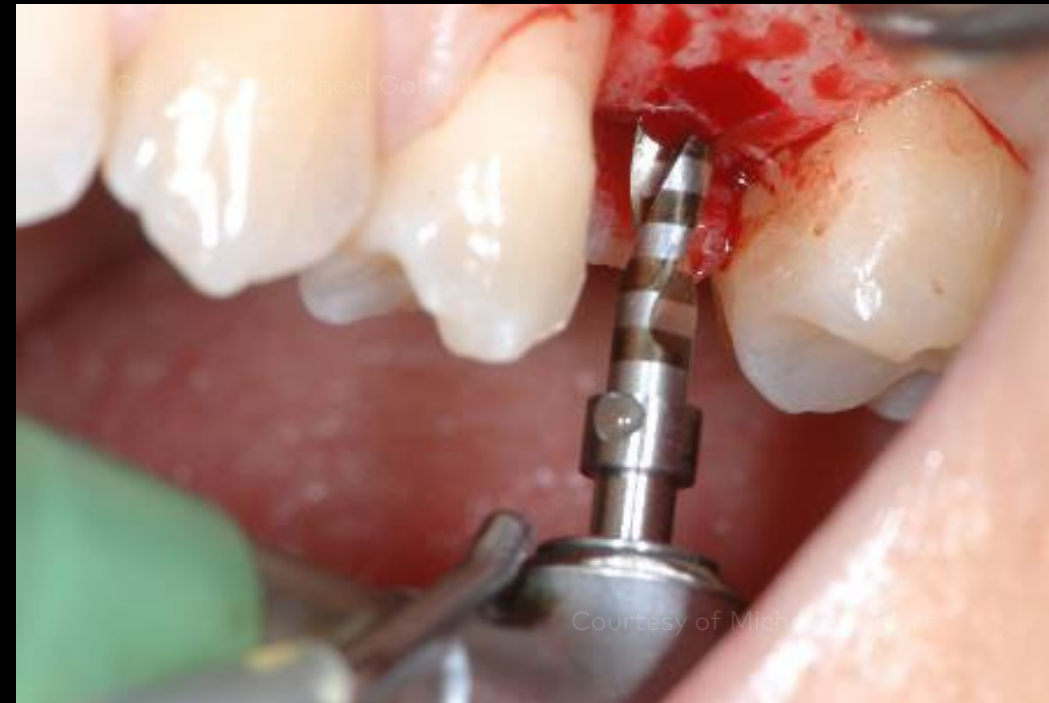Surgical procedure

Restorative procedure

Outcome



Good anatomic condition for implant insertion.



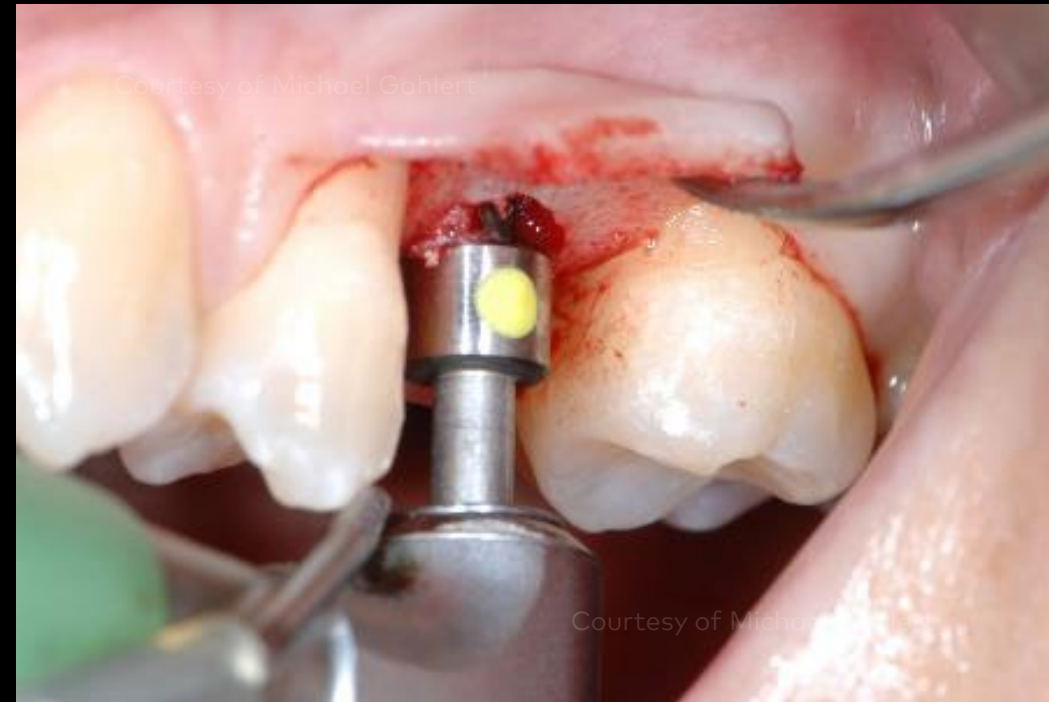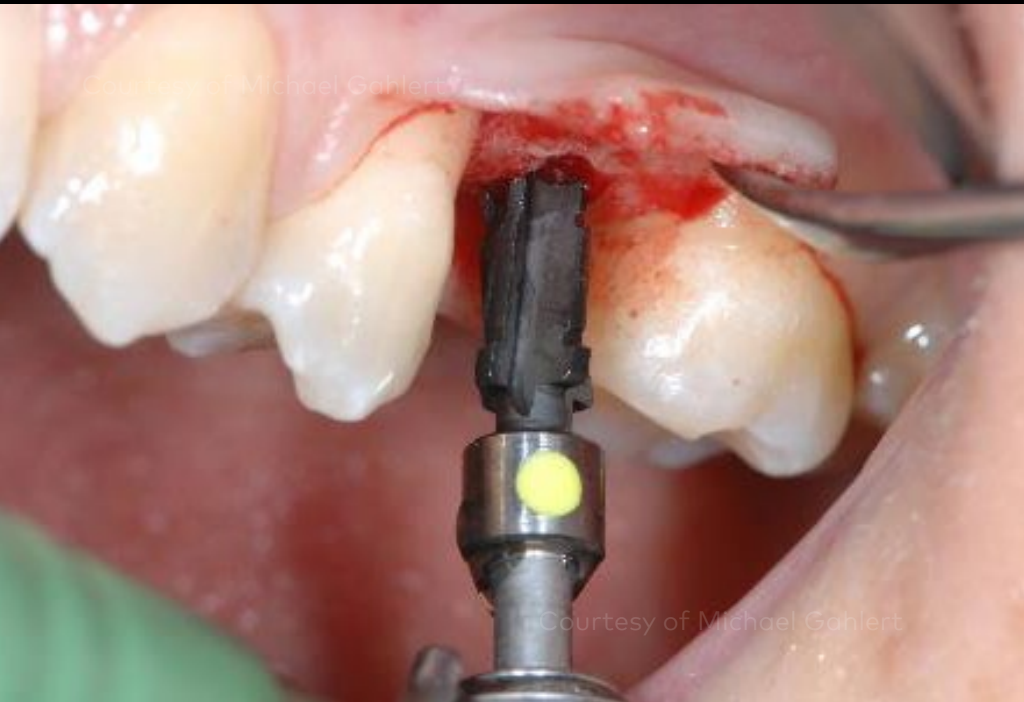Prepare implant site using NobelPearl Tapered Twist Drill.

Initial clinical situation

Surgical procedure

Restorative procedure

Outcome



NobelPearl Tapered Drill creates the tapered osteotomy. The diameter is indicated on each tool by color code (yellow for 4.2 mm diameter)


The ridge of the drill stopped at the bone level to ensure the machined collar of the implant (1.6 mm) is placed supracrestal.

Initial clinical situation

Surgical procedure

Restorative procedure

Outcome



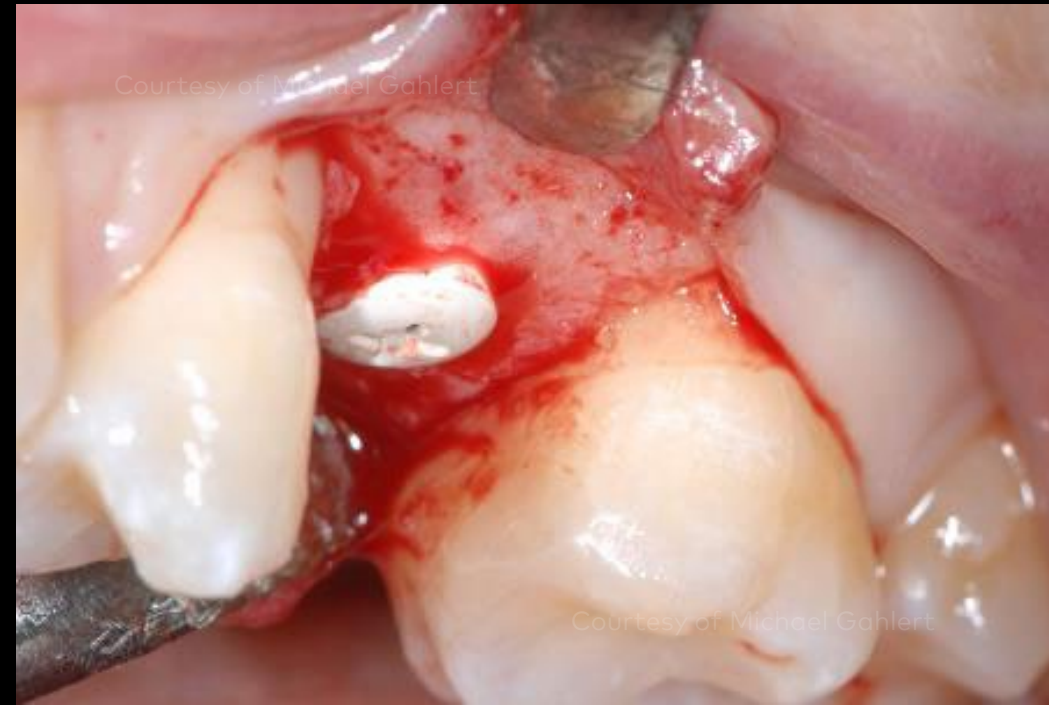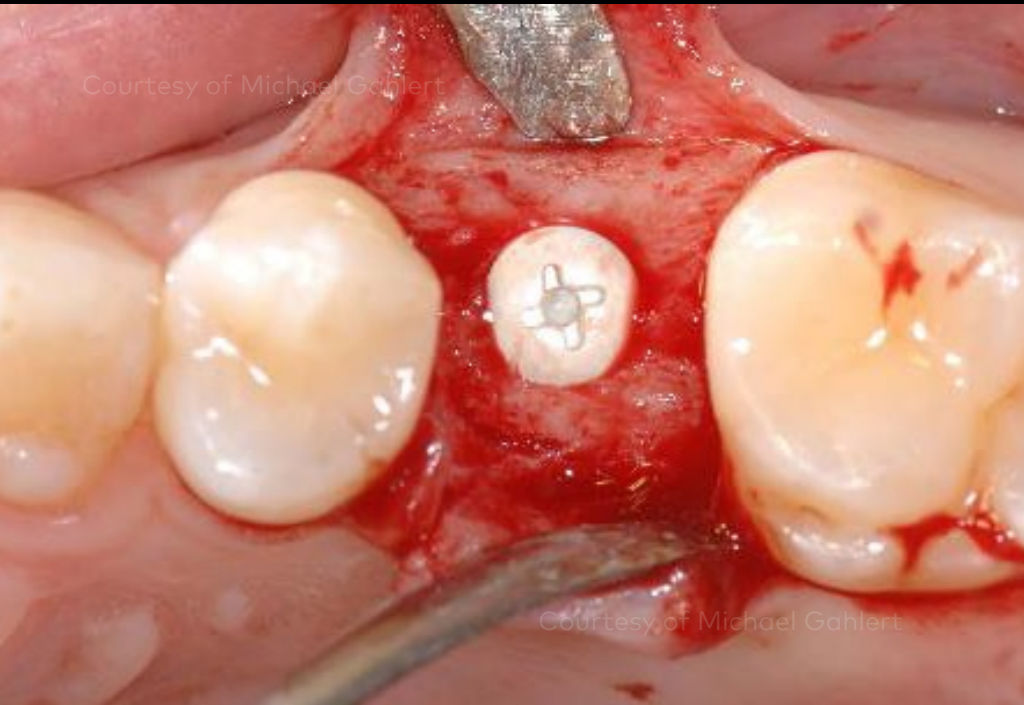Pick-up of the NobelPearl implant with the implant driver out of the sterile box.

Initial clinical situation

Surgical procedure

Restorative procedure

Outcome



Occlusal view after implant placement. PEEK Cover Screw Inter-X for closing the inner part of the implant and protecting thread during the submerged healing.

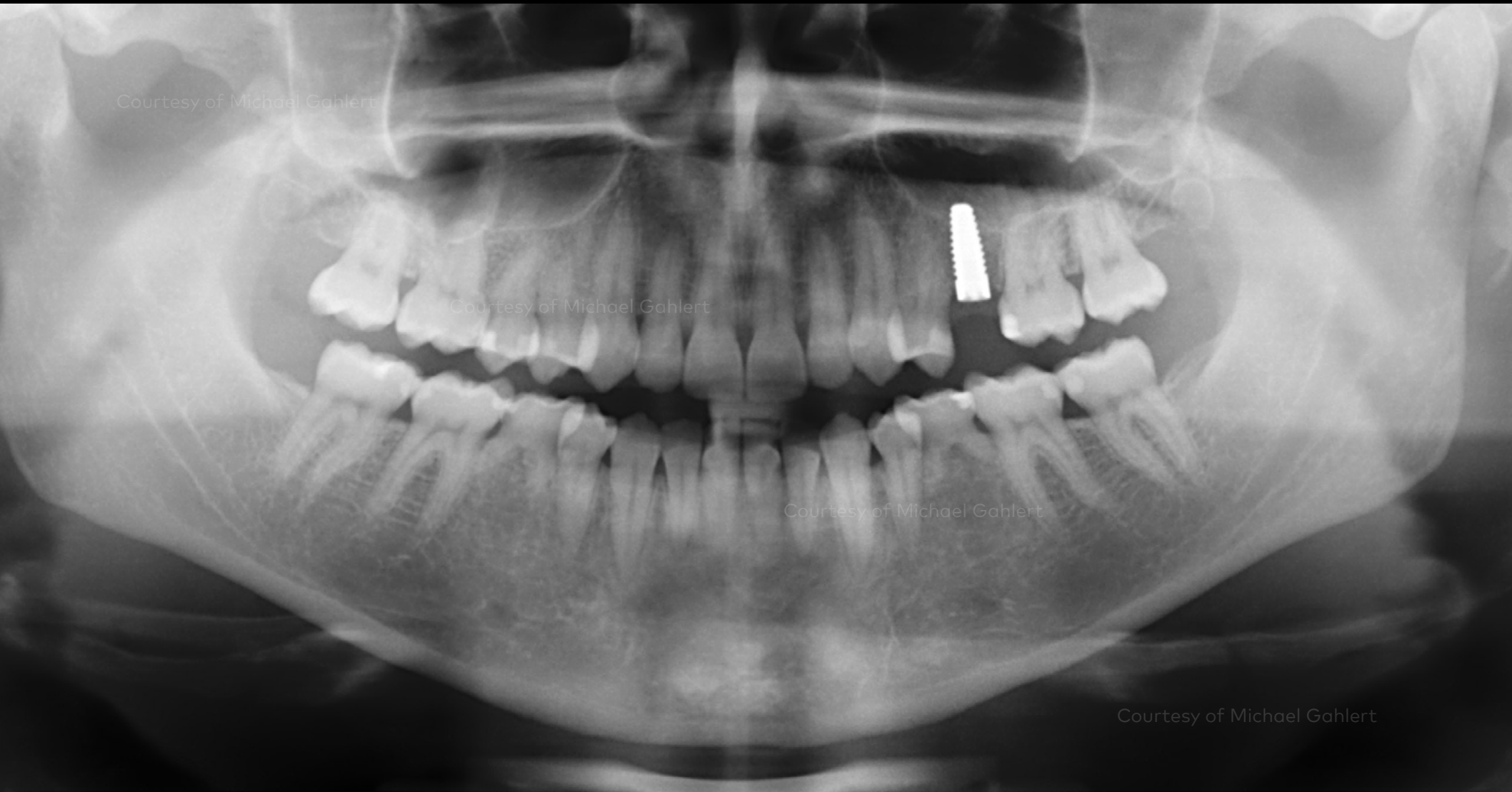Side view after implant placement. PEEK Cover Screw Inter-X for closing the inner part of the implant.

Initial clinical situation

Surgical procedure

Restorative procedure

Outcome



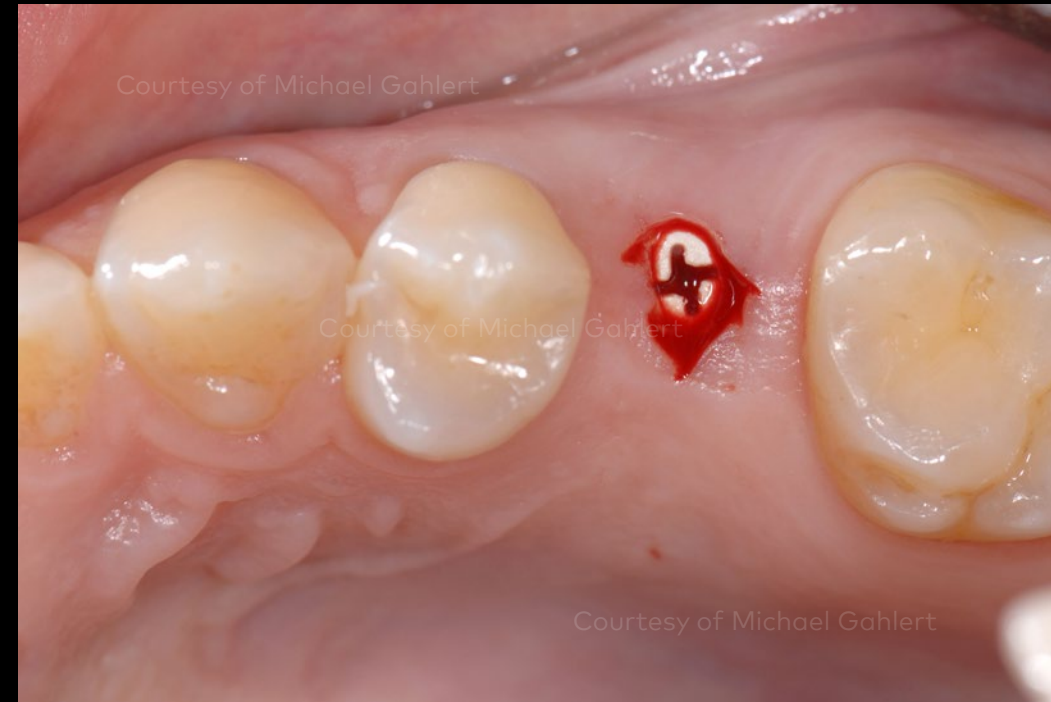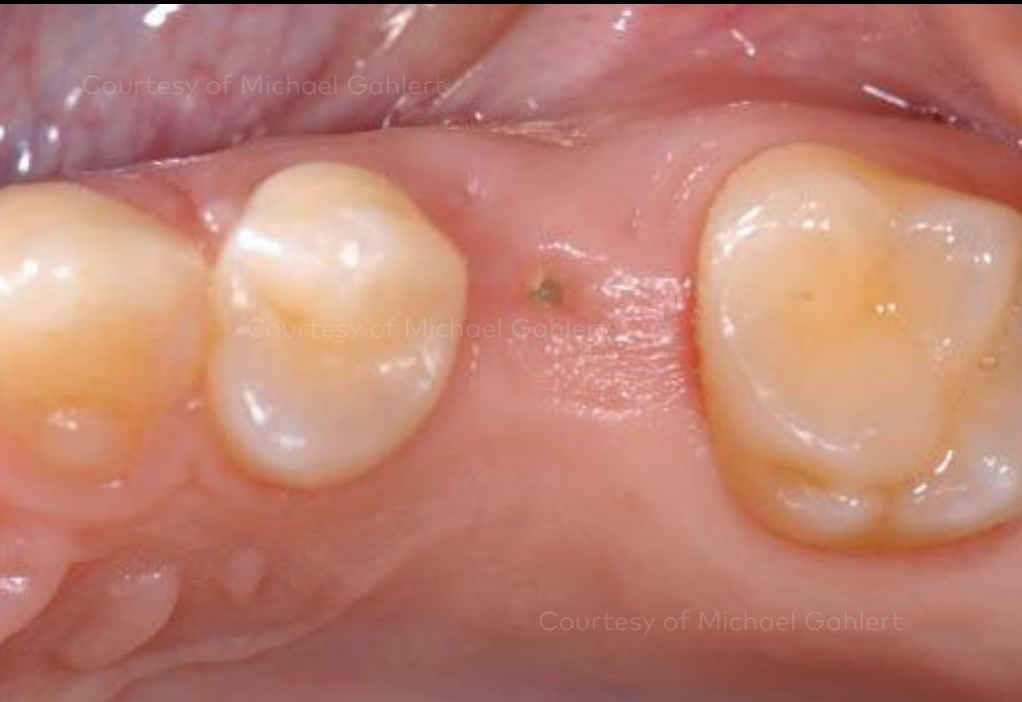OPG 2 months after implant insertion.

Initial clinical situation

Surgical procedure

Restorative procedure

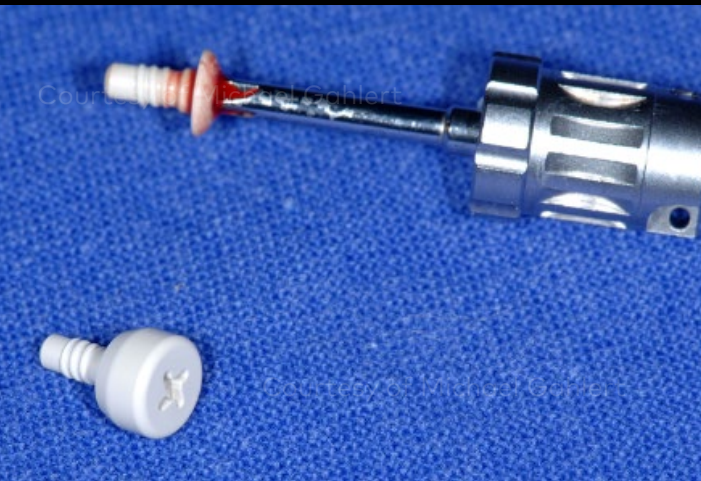Outcome



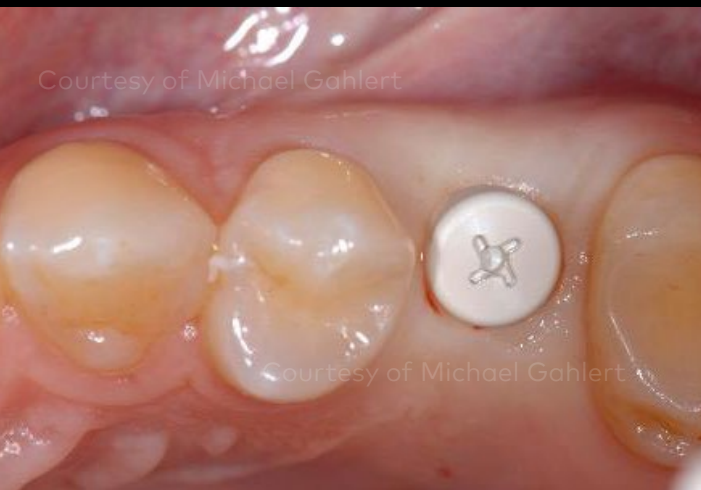Occlusal view after healing period of 3 months. Soft-tissue without any irritation was growing around the implant and on top of the cover screw.

Incision procedure as first step for prosthetic rehabilitation.

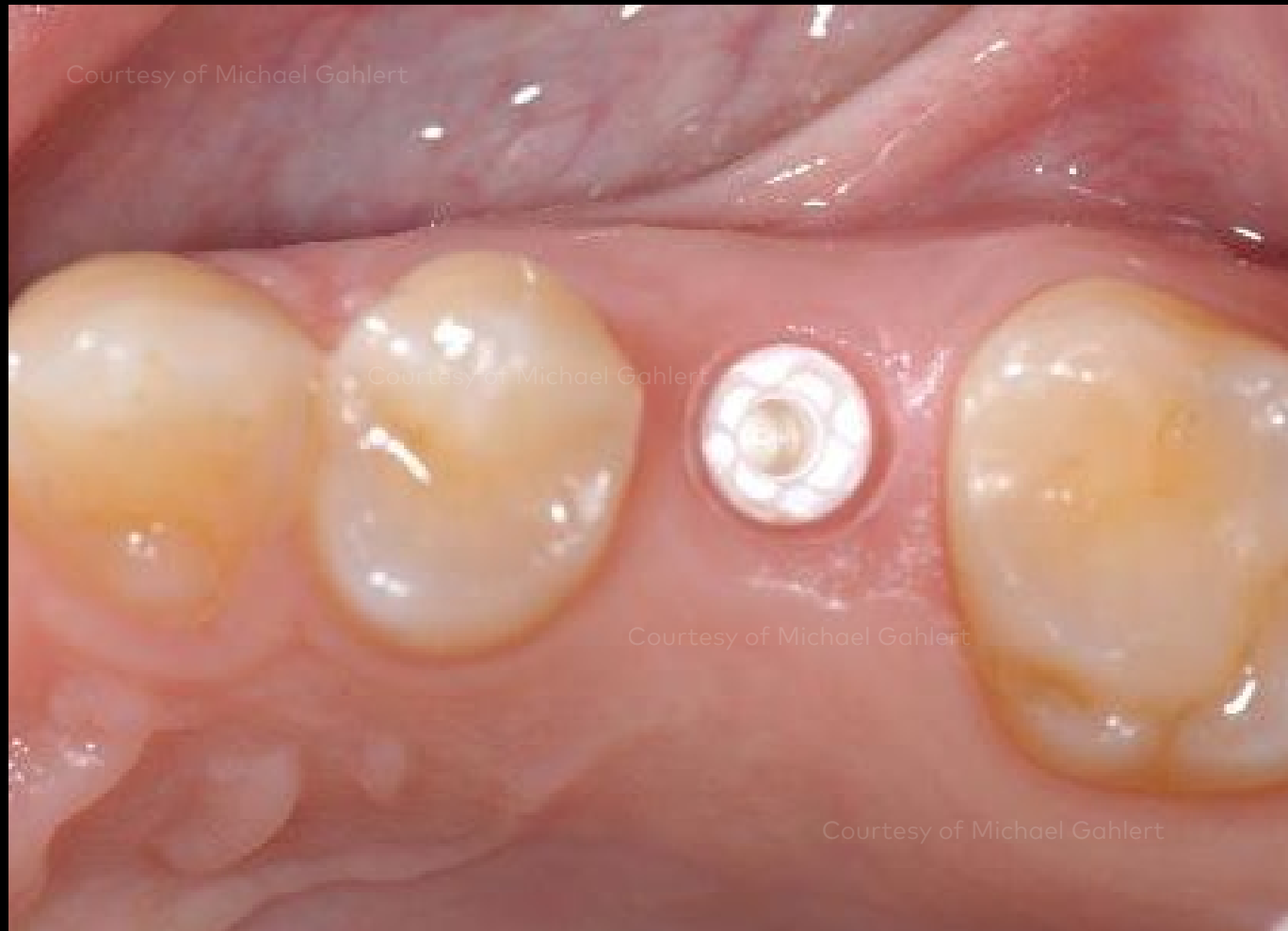Initial clinical situation



Surgical procedure



Restorative procedure



Outcome

Top. Changing the PEEK Cover Screw with a PEEK NobelPearl Healing Abutment for soft-tissue contouring.
Bottom. The PEEK NobelPearl Healing Abutment allows the soft-tissue to form around the implant shoulder and the abutment.

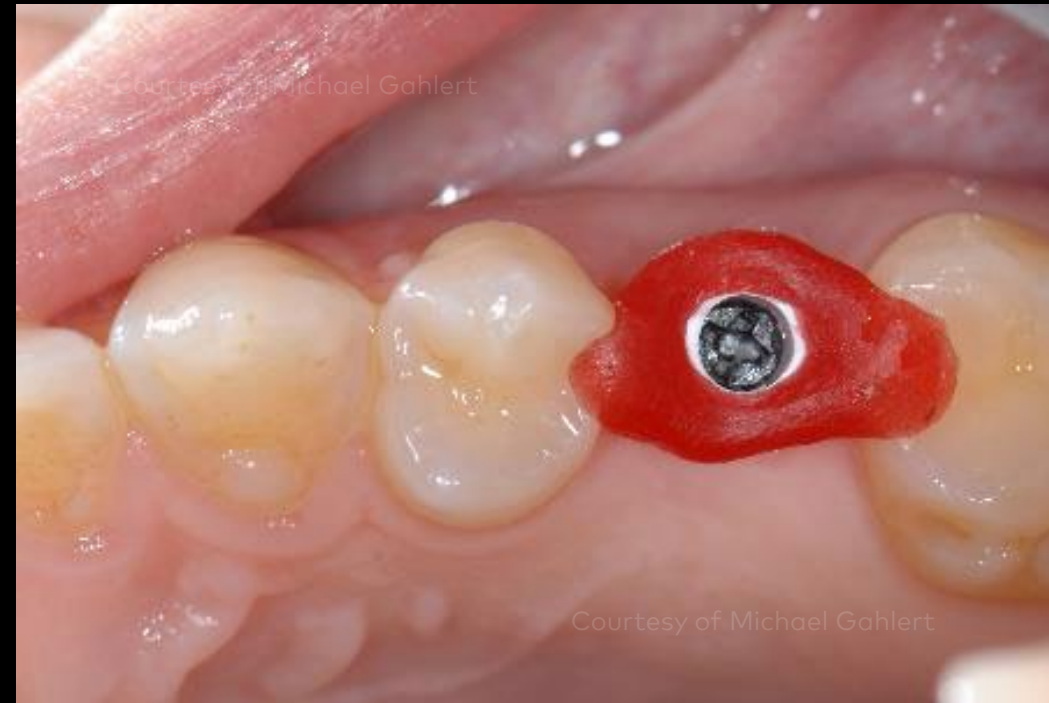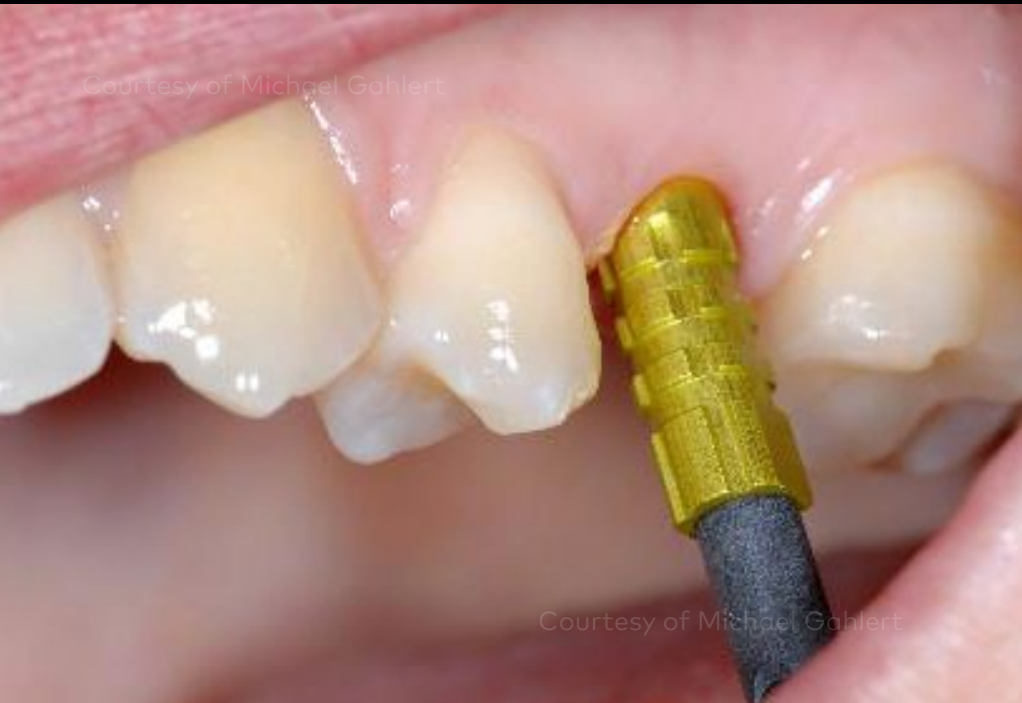Occlusal view of the NobelPearl implant after removal of the Healing Abutment. Tissue around the implant shows no irritation.

Initial clinical situation

Surgical procedure

Restorative procedure

Outcome



Screw-retained NobelPearl Impression Coping Open Tray Inter-X was screwed to the implant in order to take an impression.

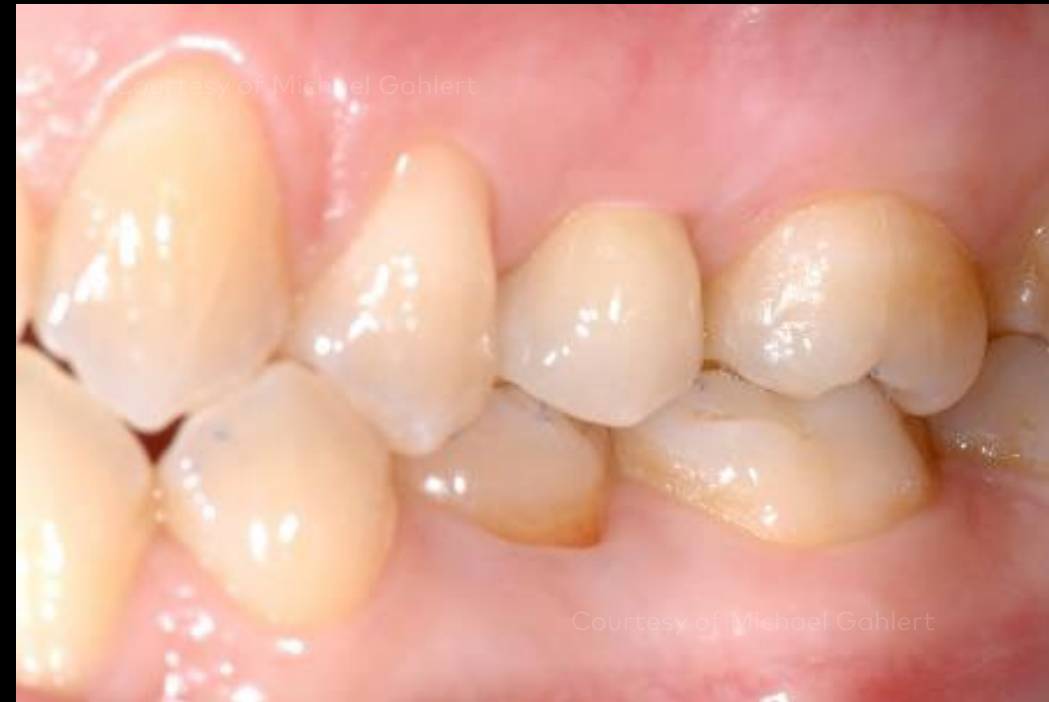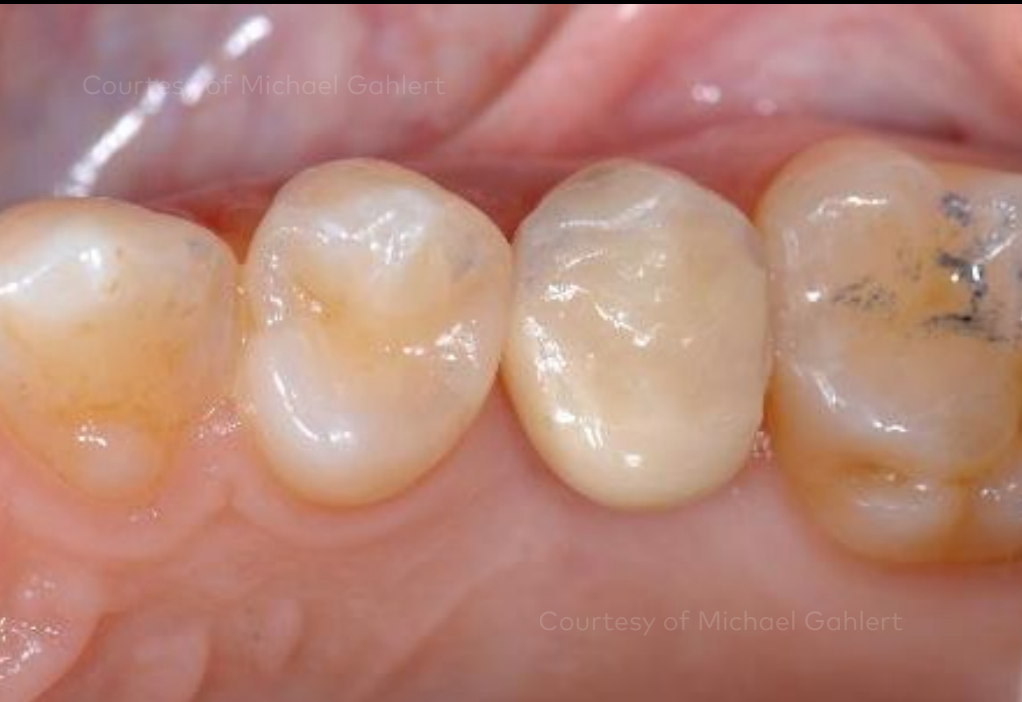Screw-retained NobelPearl ceramic abutment was fixed with a VICARBO® Clinical Screw with a torque of 25 Ncm. Pattern resin was used to position the abutment.

Initial clinical situation

Surgical procedure

Restorative procedure

Outcome



Occlusal view of final restoration. All ceramic crown fixed by Ketac™ Cem Glass ionomer cement on the ceramic abutment.

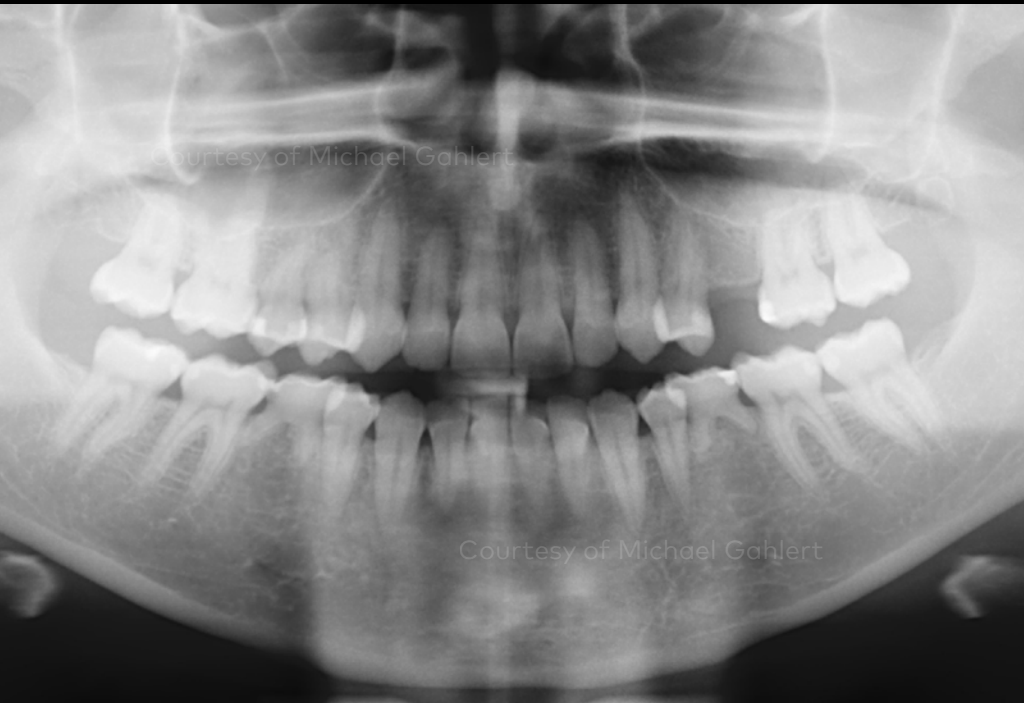Side view of final restoration.

Initial clinical situation

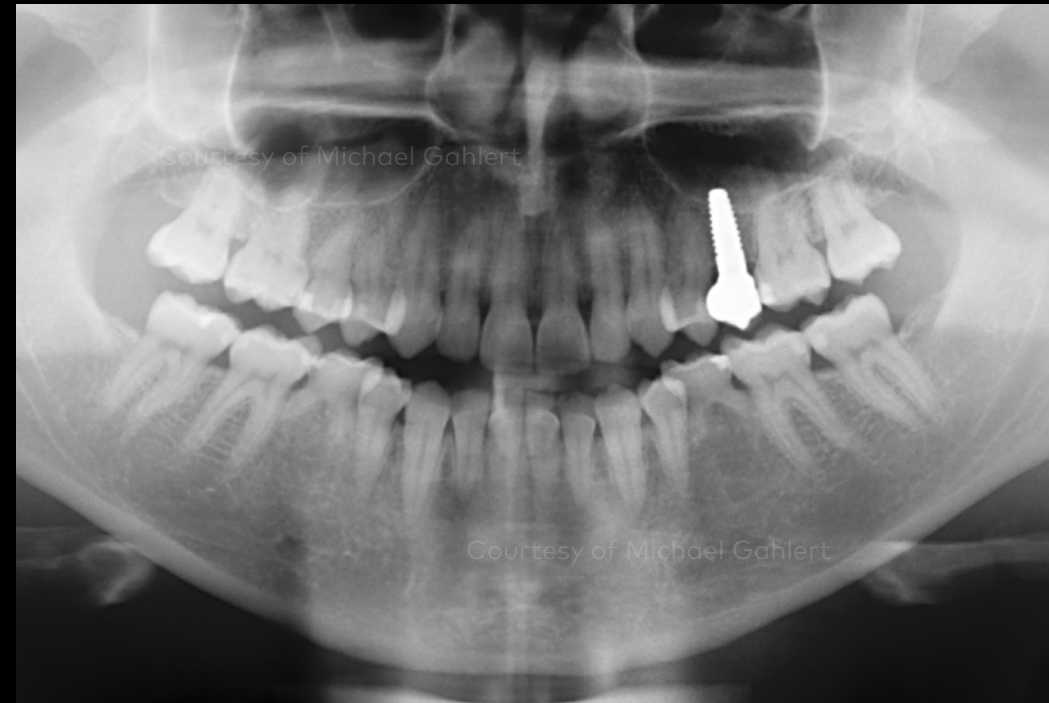
Surgical procedure

Restorative procedure

Outcome



OPG before surgery.



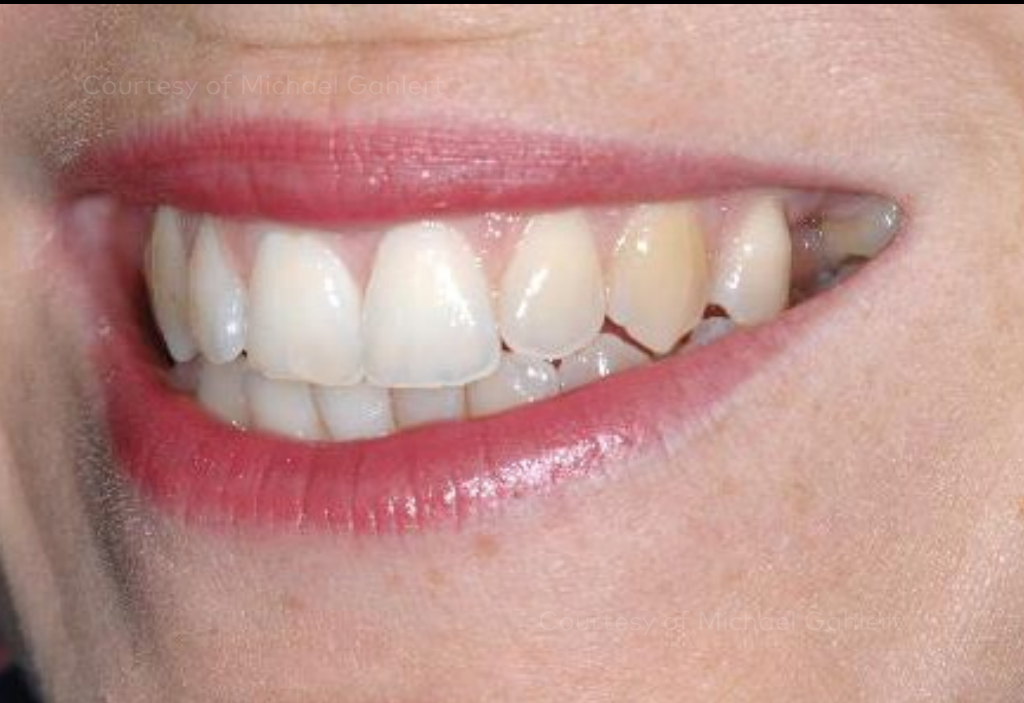OPG 3 months after surgery.

Initial clinical situation

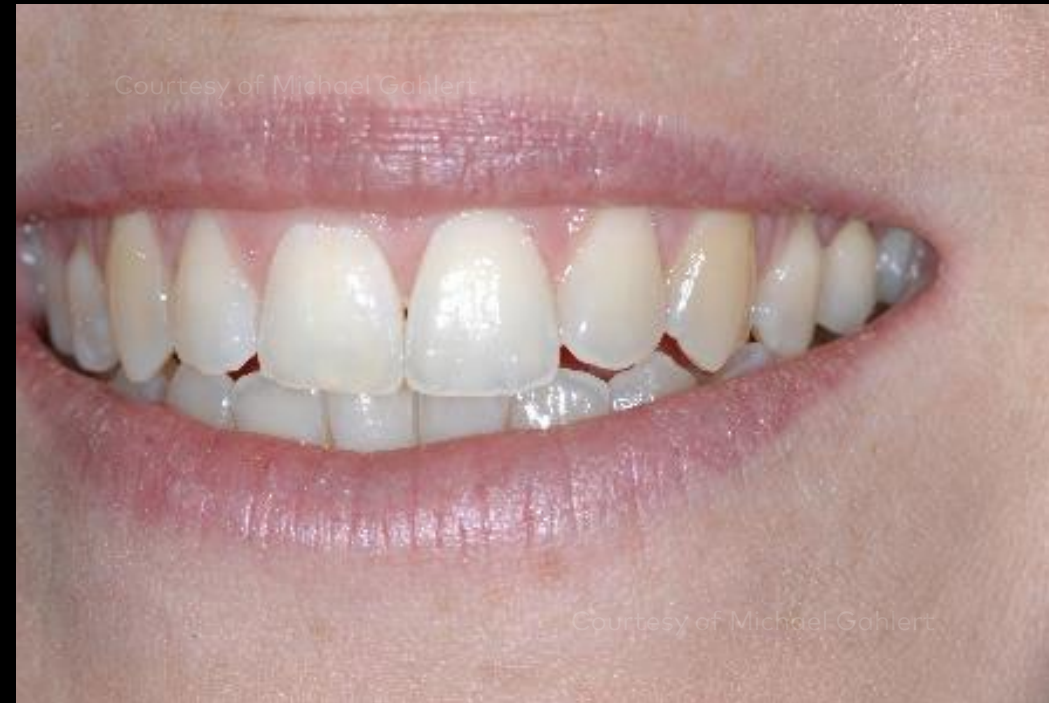Surgical procedure

Restorative procedure

Outcome



Lip line during smiling shows the tooth gap before surgery.



Lip line during smiling shows the natural appearance and the esthetic result at 3 months after surgery.

Case courtesy of Michael Gahlert

