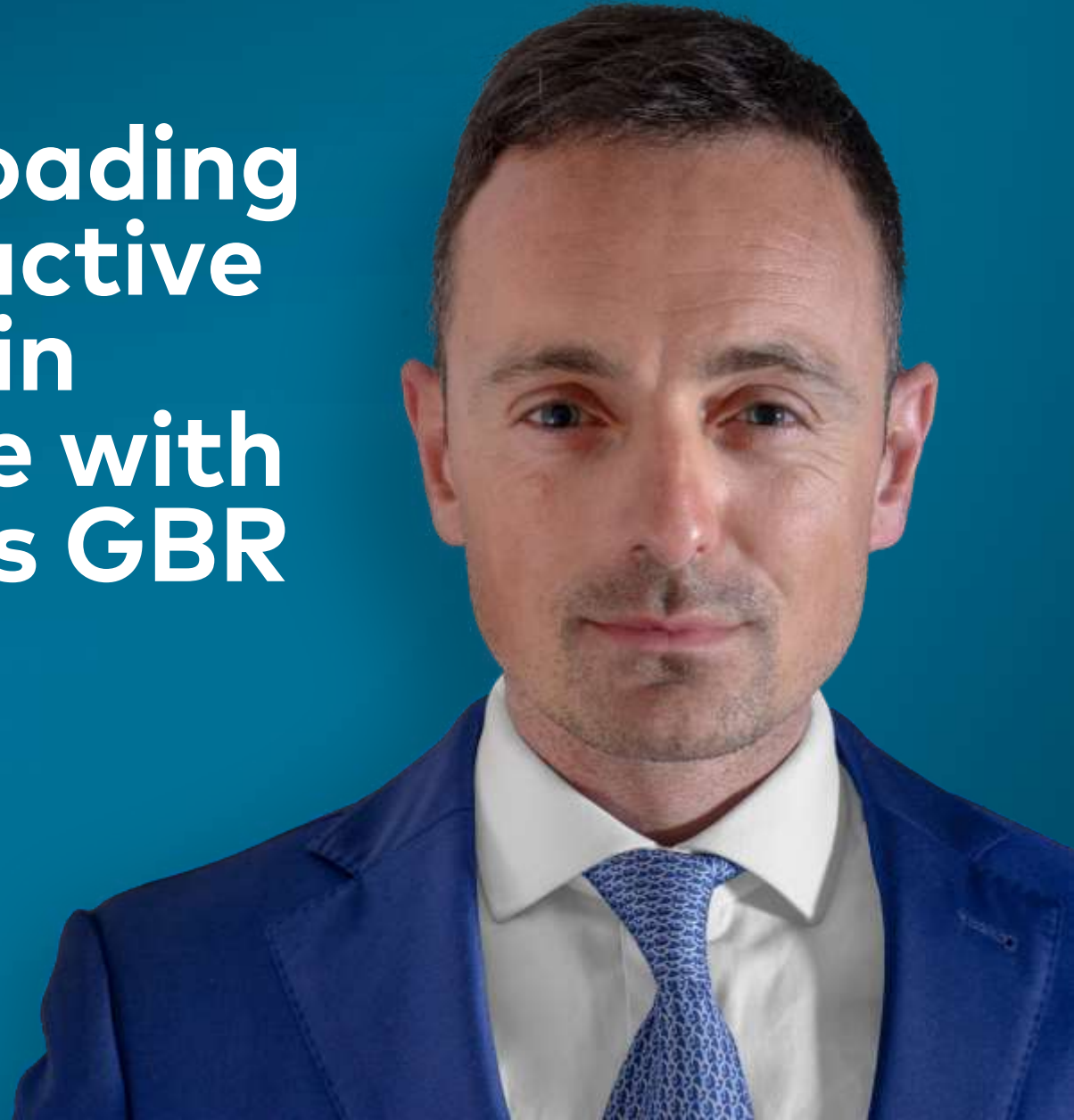

Immediate loading of post extractive single tooth in esthetic zone with simultaneous GBR

Dr. Fabrizio Colombo, DDS
Milan, Italy





Dr. Fabrizio Colombo, DDS

Patient

69 years old, male, no systemic diseases, no oral pathology or dental problems.

Clinical situation

Presence of a damaged upper left first premolar.

Surgical solution

Extraction of 24, simultaneous placement of a NobelReplace® CC 4.3x11.5 and filling of the buccal gap using creos™ xenogain.

Restorative solution

Provisional: immediate loading using a screwed acrylic crown (temporary abutment engaging).
Final: screwed zirconia crown.

Surgery date(s)

November 22, 2018.

Total treatment time

7 months.

Tooth position(s)

Upper left first premolar.



Initial clinical situation

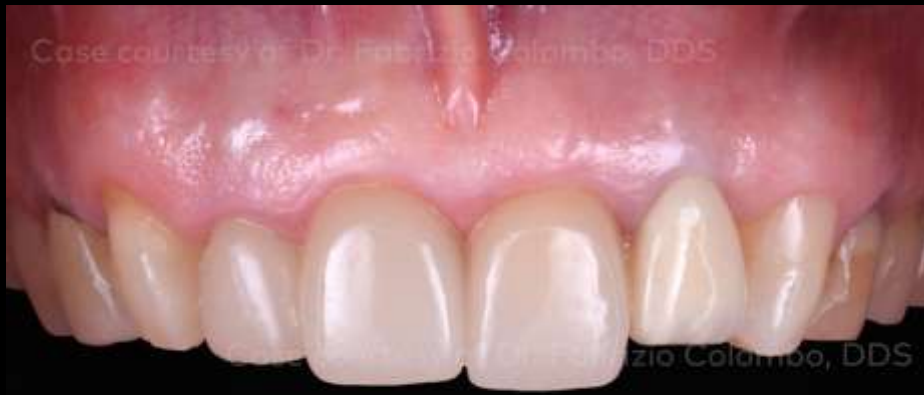Treatment planning

Surgical procedure

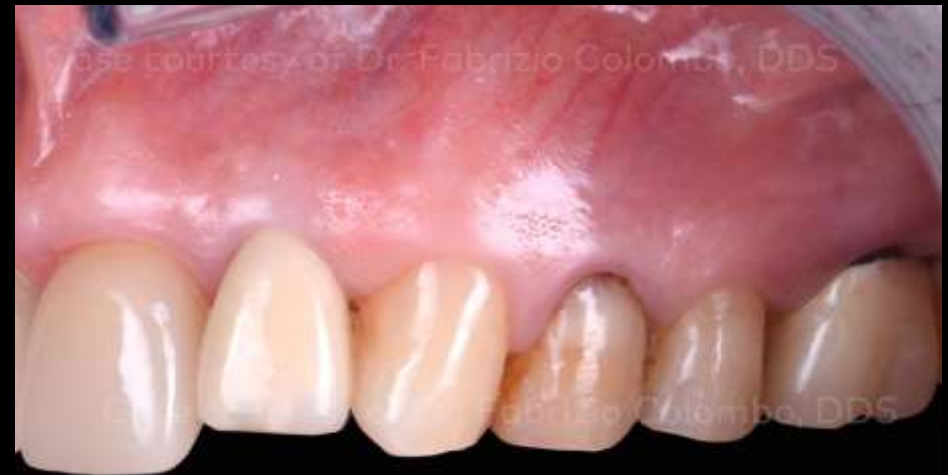Restorative procedure

Outcome

Immediate loading of post extractive single tooth in esthetic zone with simultaneous GBR



Initial clinical situation – front view.



Initial clinical situation – Buccal view.

Initial clinical situation

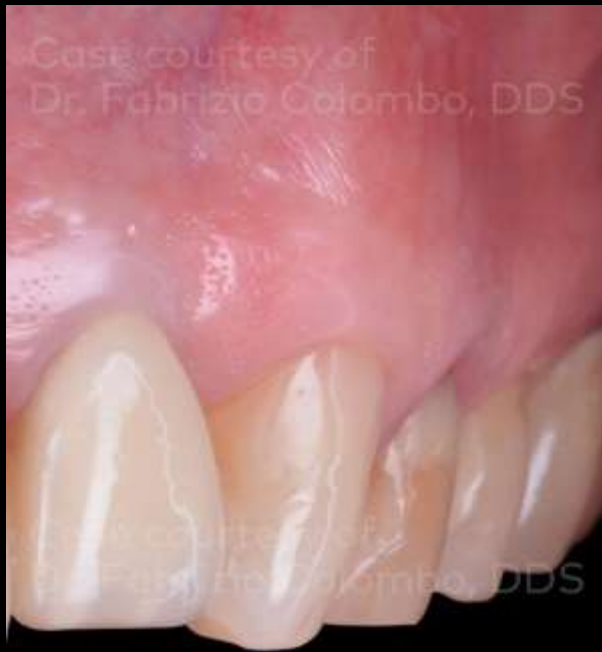Treatment planning

Surgical procedure

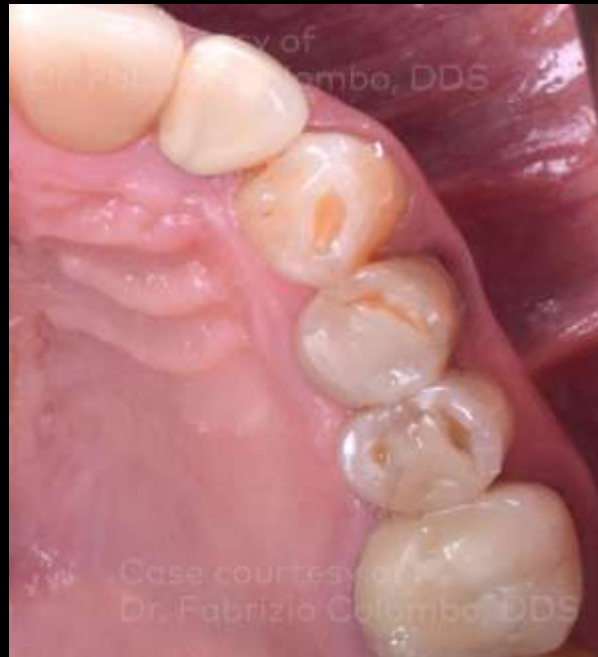Restorative procedure

Outcome

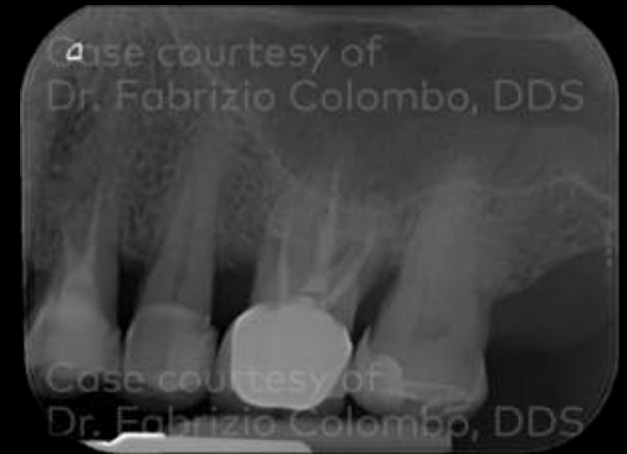Immediate loading of post extractive single tooth in esthetic zone with simultaneous GBR



Detail of the typical buccal convex architecture in the area of 24 (frontal view).



Detail of the typical buccal convex architecture in the area of 24 (occlusal view).



Pre-operative X-ray.

Initial clinical situation

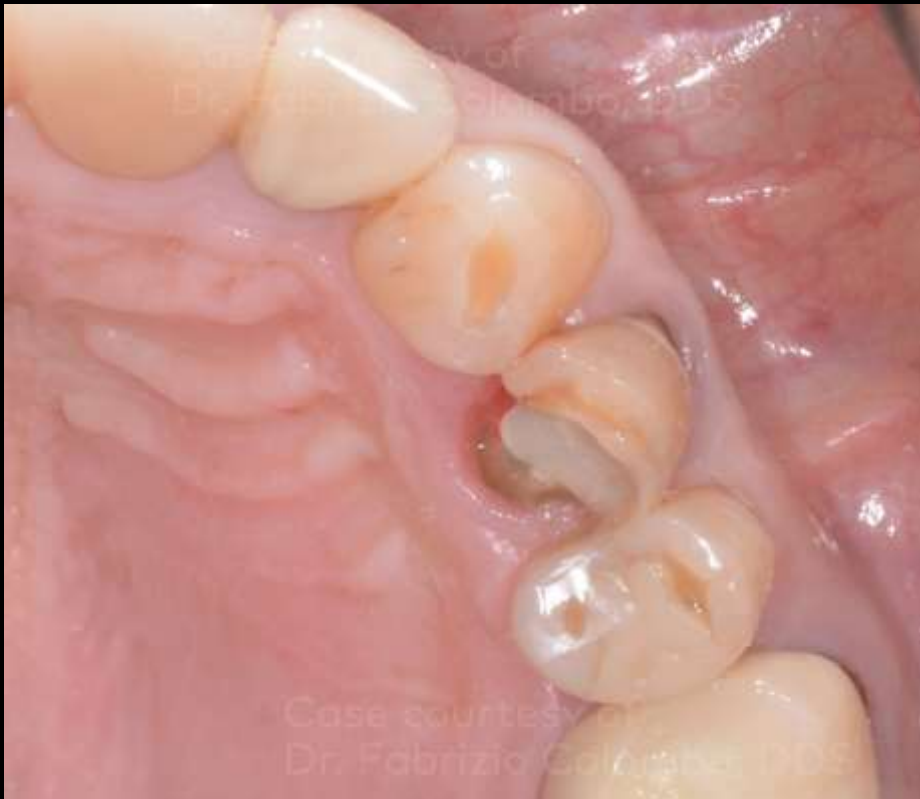Treatment planning

Surgical procedure

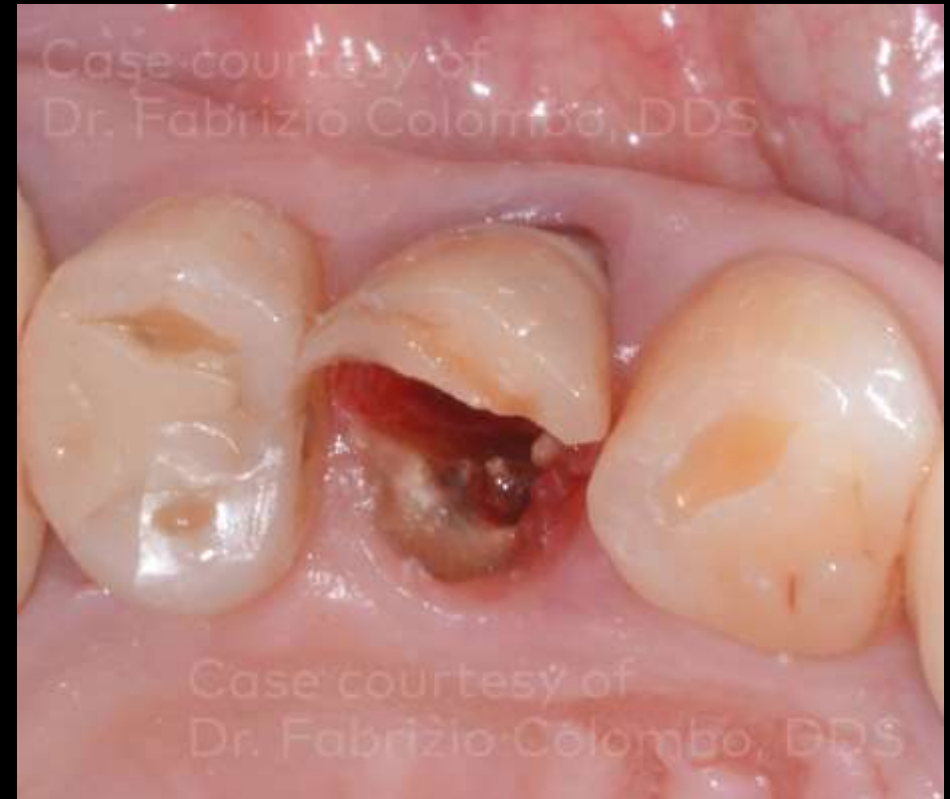Restorative procedure

Outcome

Immediate loading of post extractive single tooth in esthetic zone with simultaneous GBR



Loss of the palatal wall of the crown on 24.



Vertical fracture on 24.

Initial clinical situation

Treatment planning

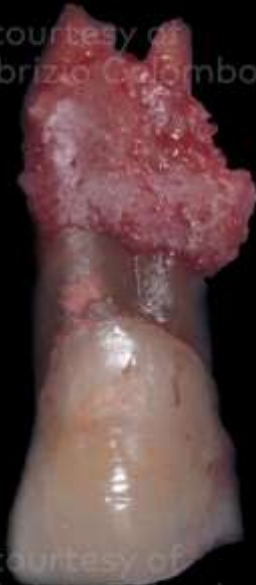Surgical procedure

Restorative procedure

Outcome

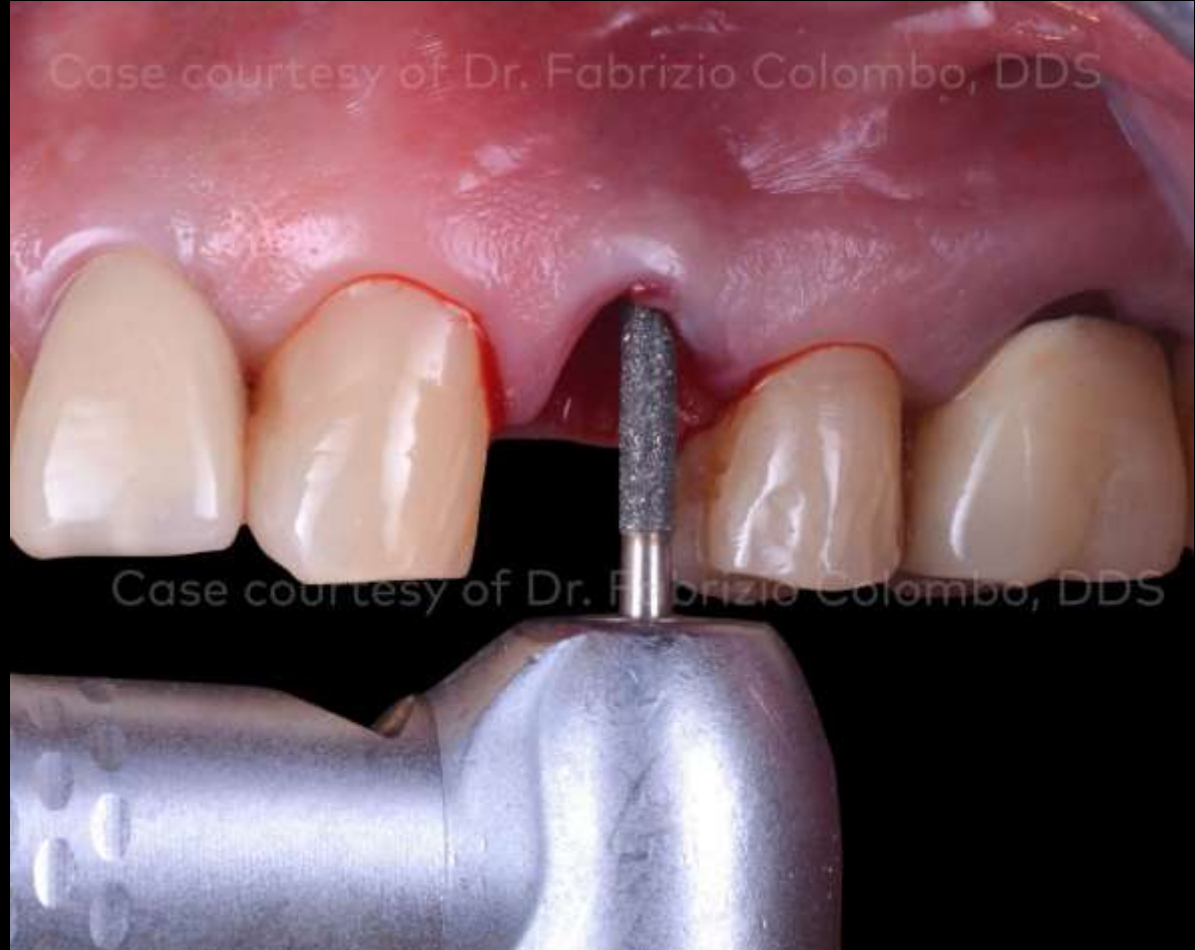Immediate loading of post extractive single tooth in esthetic zone with simultaneous GBR

Case courtesy of
Dr. Fabrizio Colombo, DDS



Case courtesy of
Dr. Fabrizio Colombo, DDS

Detail of 24 after extraction; presence of two vestibular roots and an accidental fracture of the buccal bone plate.



Leveling and cleaning of the buccal wall.

Initial clinical situation

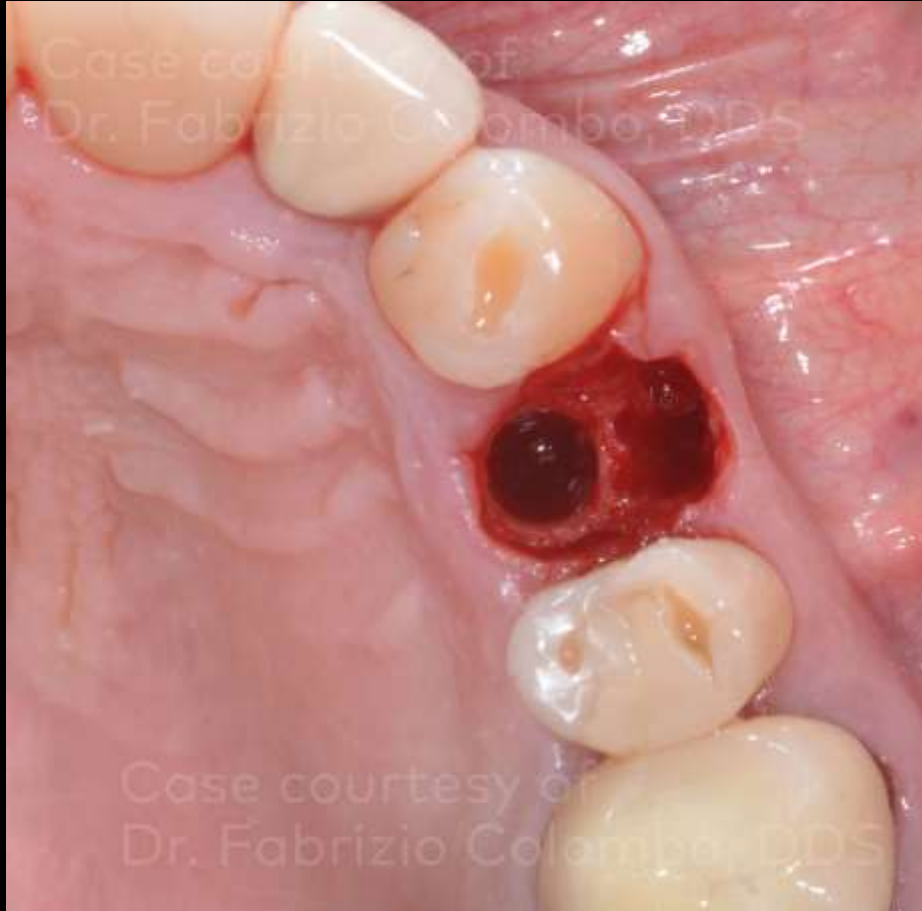
Treatment planning

Surgical procedure

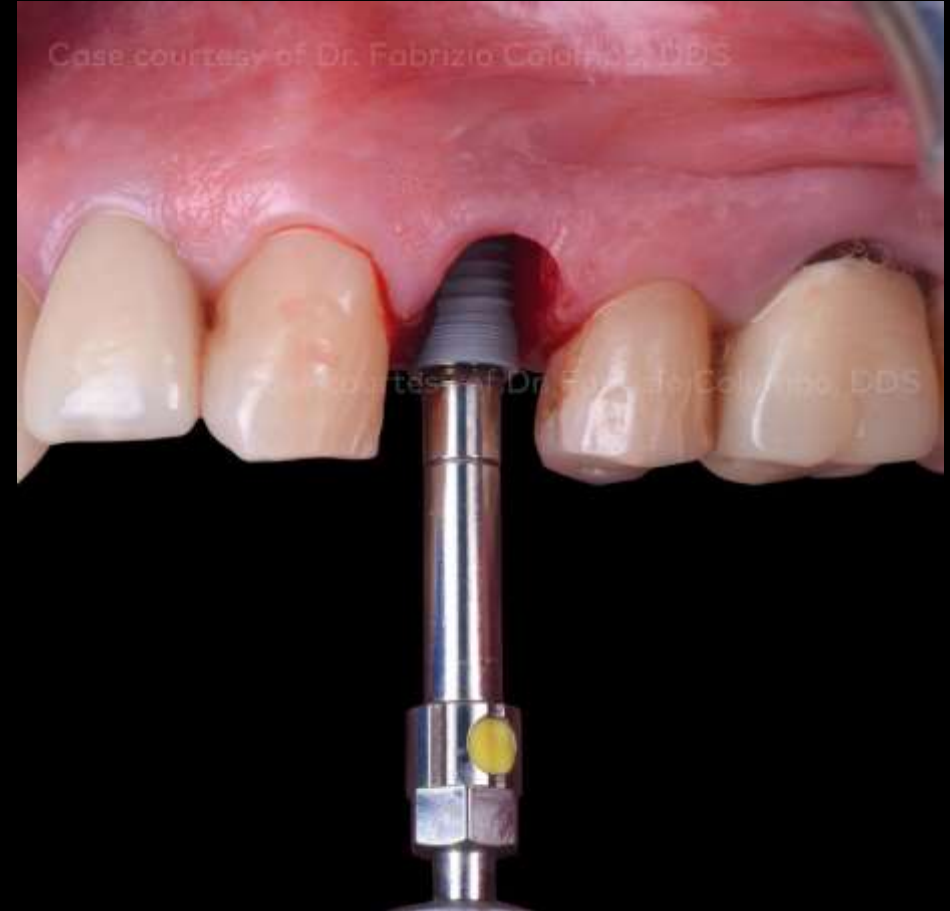Restorative procedure

Outcome

Immediate loading of post extractive single tooth in esthetic zone with simultaneous GBR



Detail of the implant site preparation in the alveolus palatal region. The interdental septum has become the new buccal cortical bone around the implant.



NobelReplace® CC 4.3 x 11.5 mm insertion (35 Ncm).

Initial clinical situation

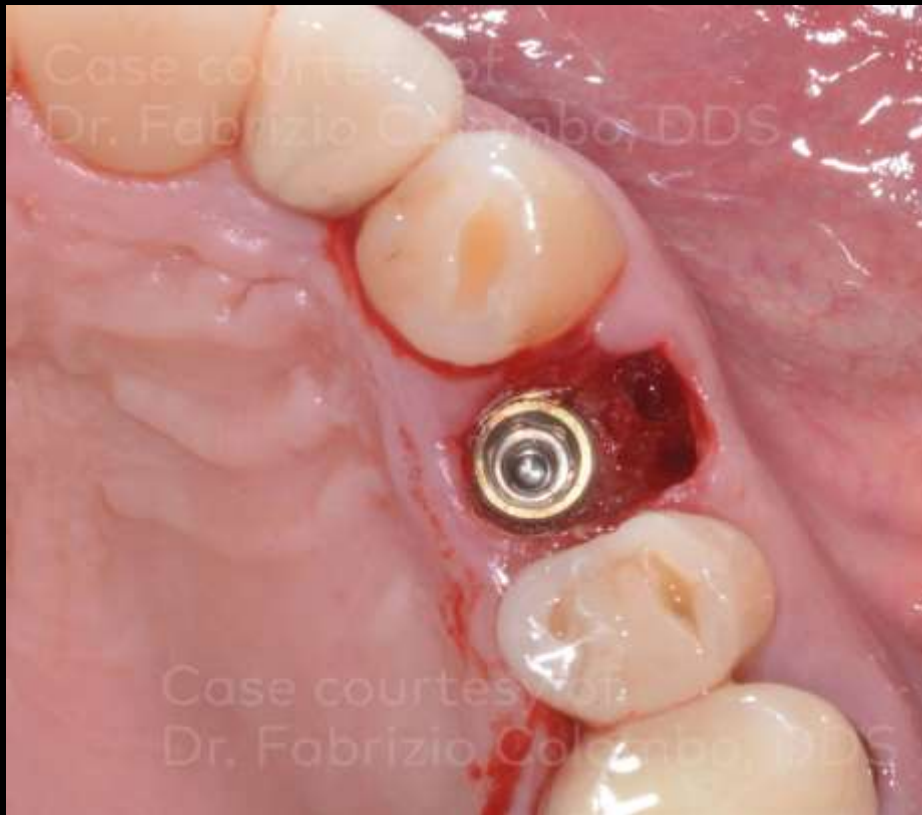Treatment planning

Surgical procedure

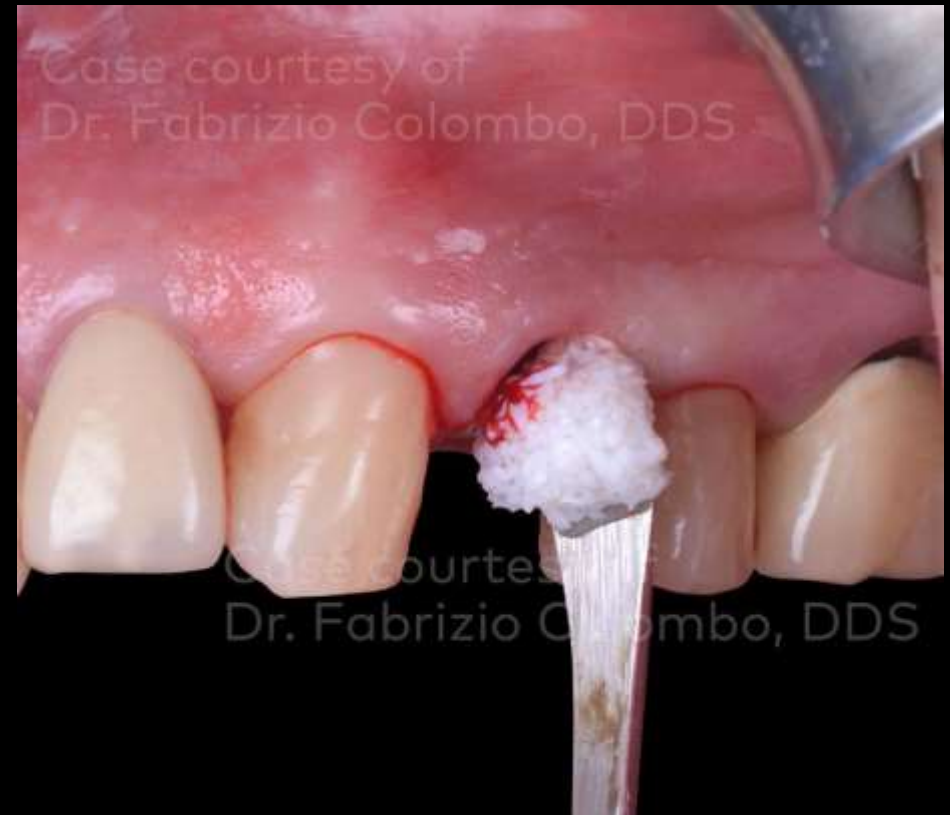Restorative procedure

Outcome

Immediate loading of post extractive single tooth in esthetic zone with simultaneous GBR



Occlusal detail of the implant placement.



The socket is filled using creos™ xenogain 0.5 g small granules.

Initial clinical situation

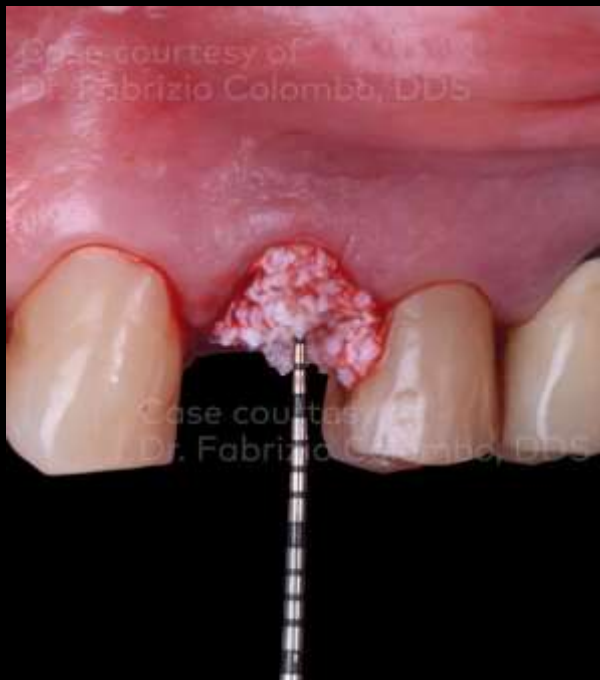Treatment planning

Surgical procedure

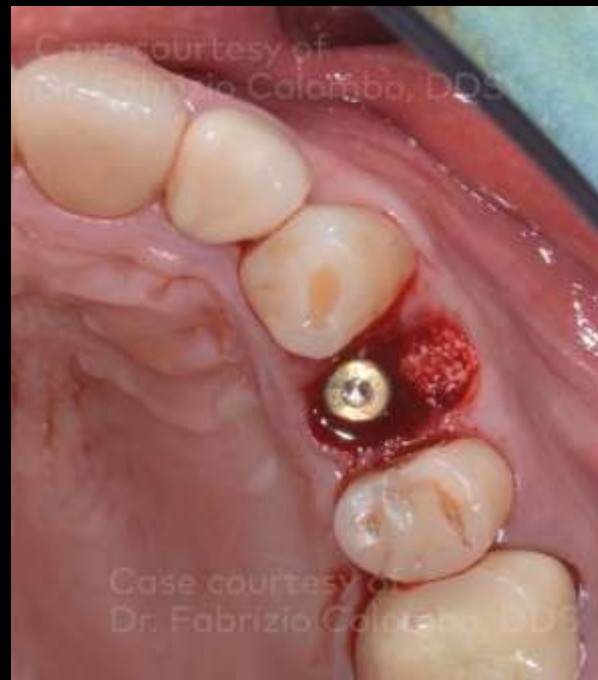Restorative procedure

Outcome

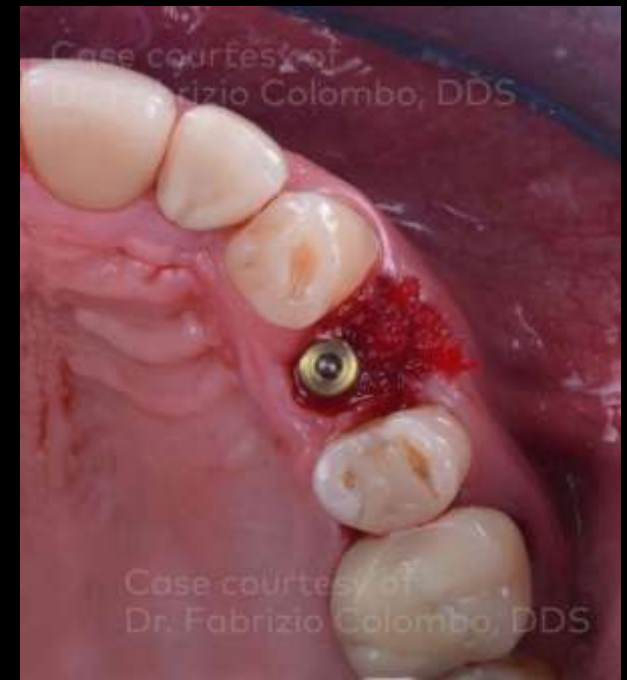Immediate loading of post extractive single tooth in esthetic zone with simultaneous GBR



Insertion of the graft in the buccal socket.



View of the biomaterial placed.



Temporary protection of the graft with fibrin sponge.

Initial clinical situation

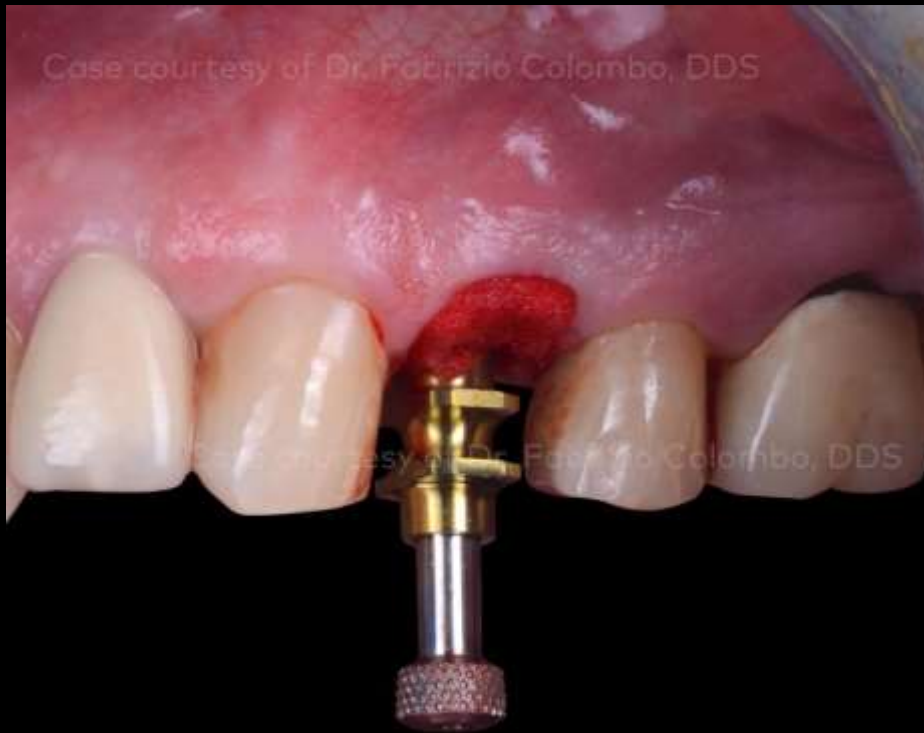Treatment planning

Surgical procedure

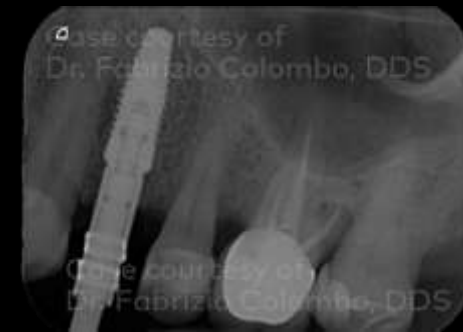Restorative procedure

Outcome

Immediate loading of post extractive single tooth in esthetic zone with simultaneous GBR



Impression phase.



X-ray taken during the impression phase.

Initial clinical situation

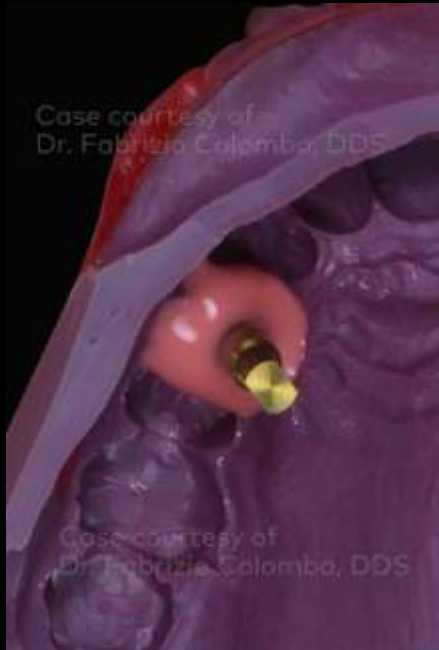Treatment planning

Surgical procedure

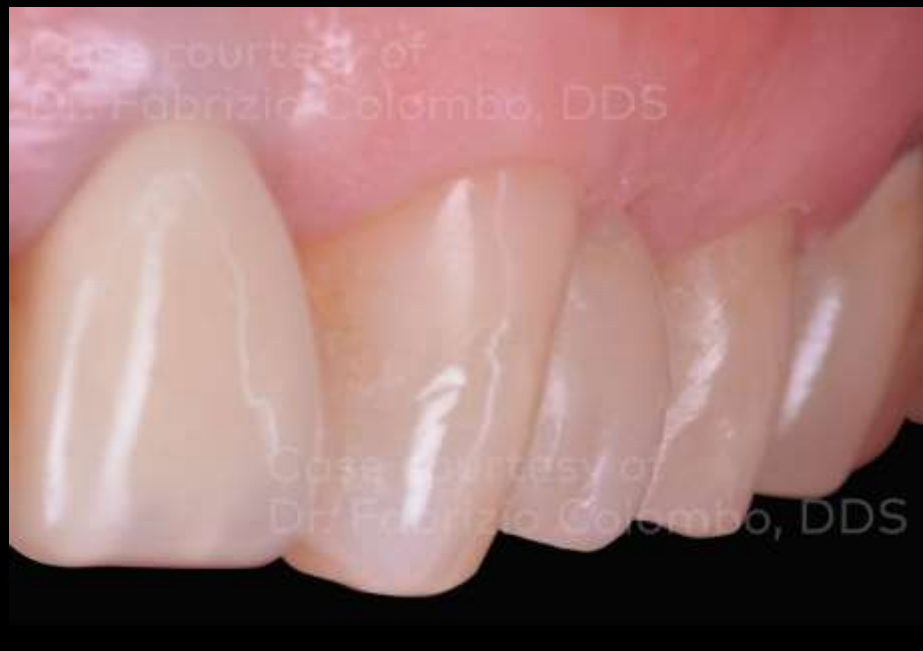Restorative procedure

Outcome

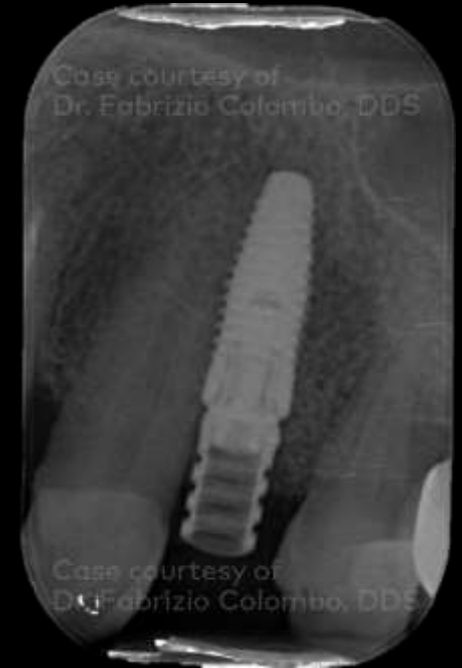Immediate loading of post extractive single tooth in esthetic zone with simultaneous GBR



Detail of the impression (Impregum 3M ESPE).



Temporary screwed crown a few days after surgical phase.



Temporary crown X-ray.

Initial clinical situation

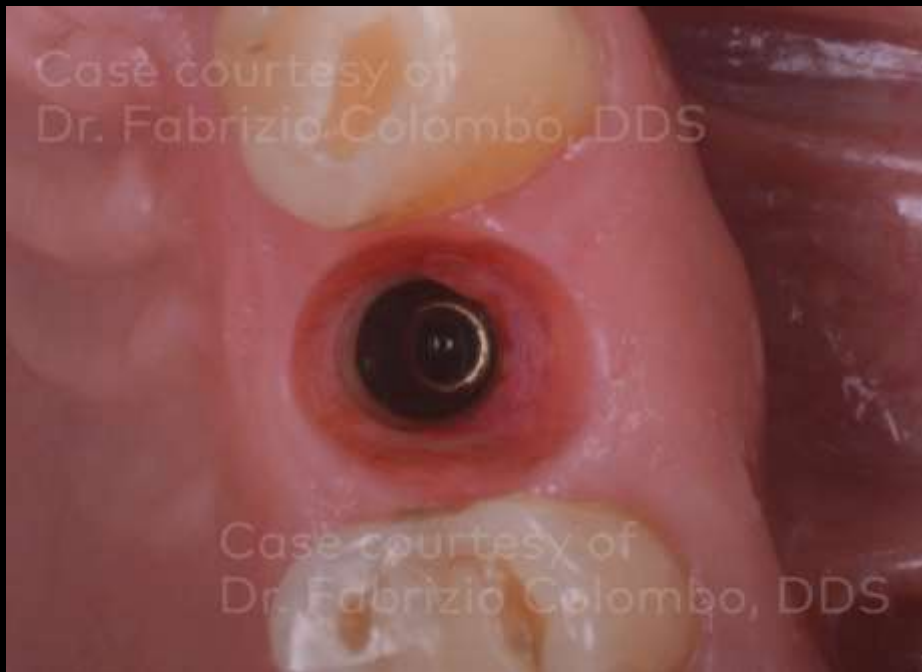Treatment planning

Surgical procedure

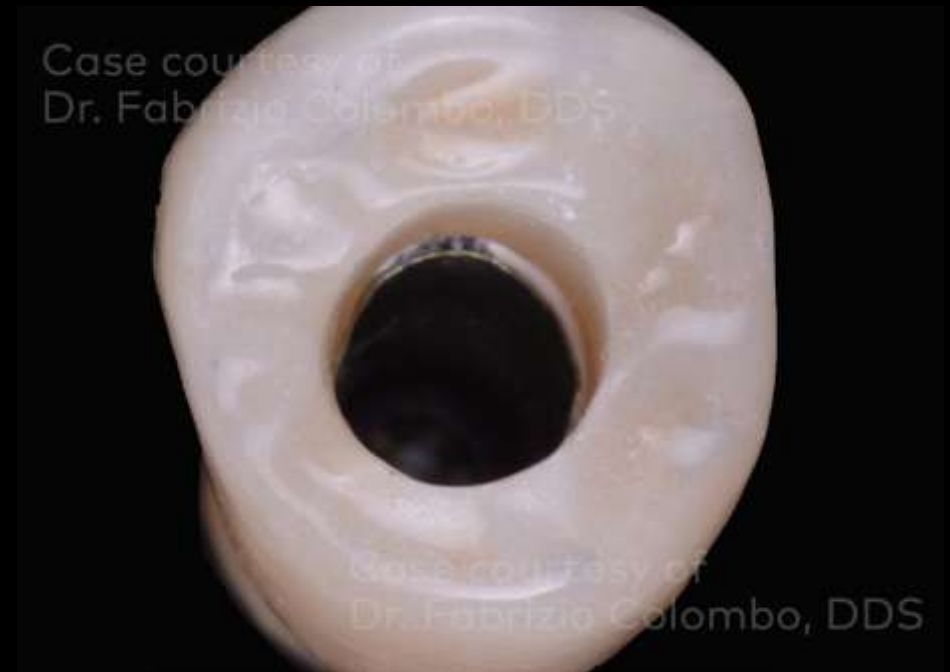Restorative procedure

Outcome

Immediate loading of post extractive single tooth in esthetic zone with simultaneous GBR



Final clinical situation of the gingival tunnel (occlusal view). Detail of the buccal convex architecture (7 months after implant placement).



Final zirconia screwed crown (occlusal view).

Initial clinical
situation

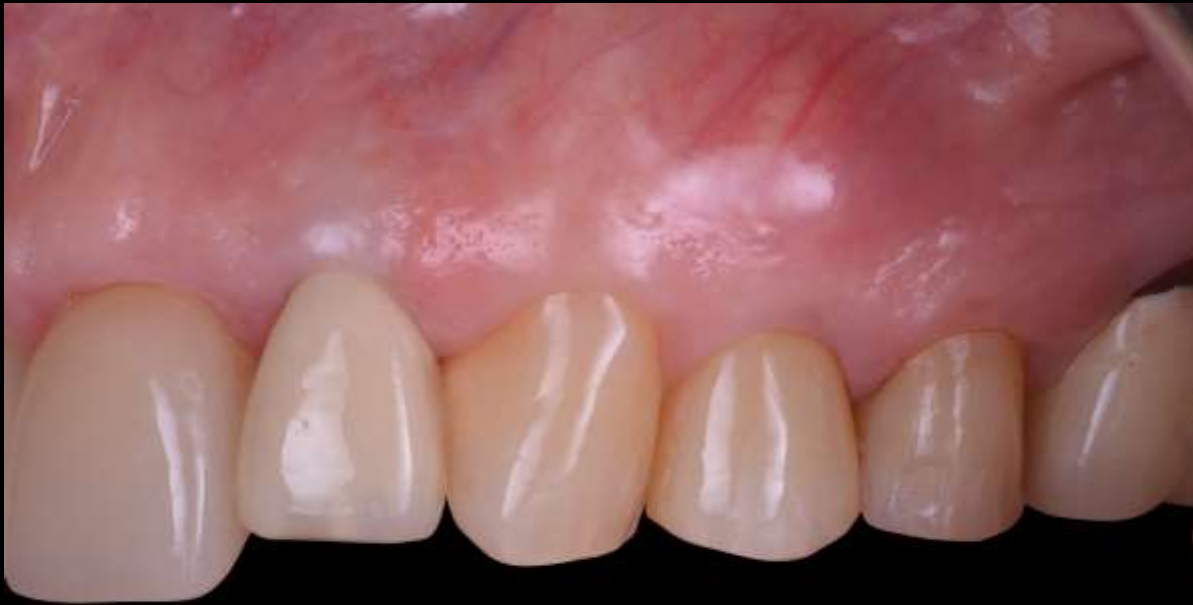Treatment
planning

Surgical
procedure

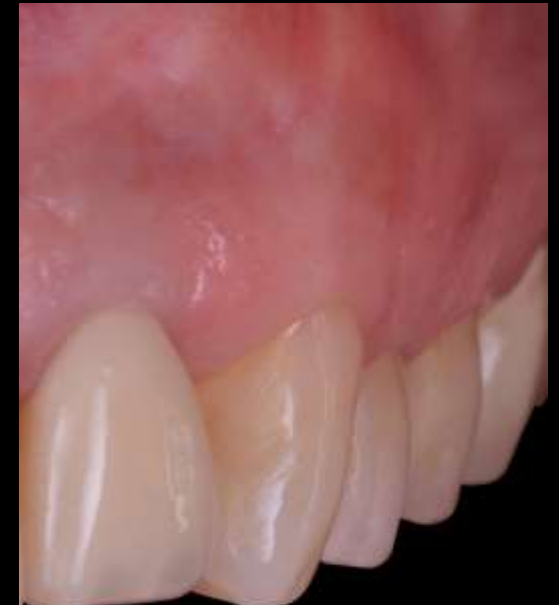Restorative
procedure

Outcome

Immediate loading of post extractive single tooth in esthetic zone with simultaneous GBR



Final ceramic screwed crown
(lateral view, 7 months after implant placement).



Initial clinical situation

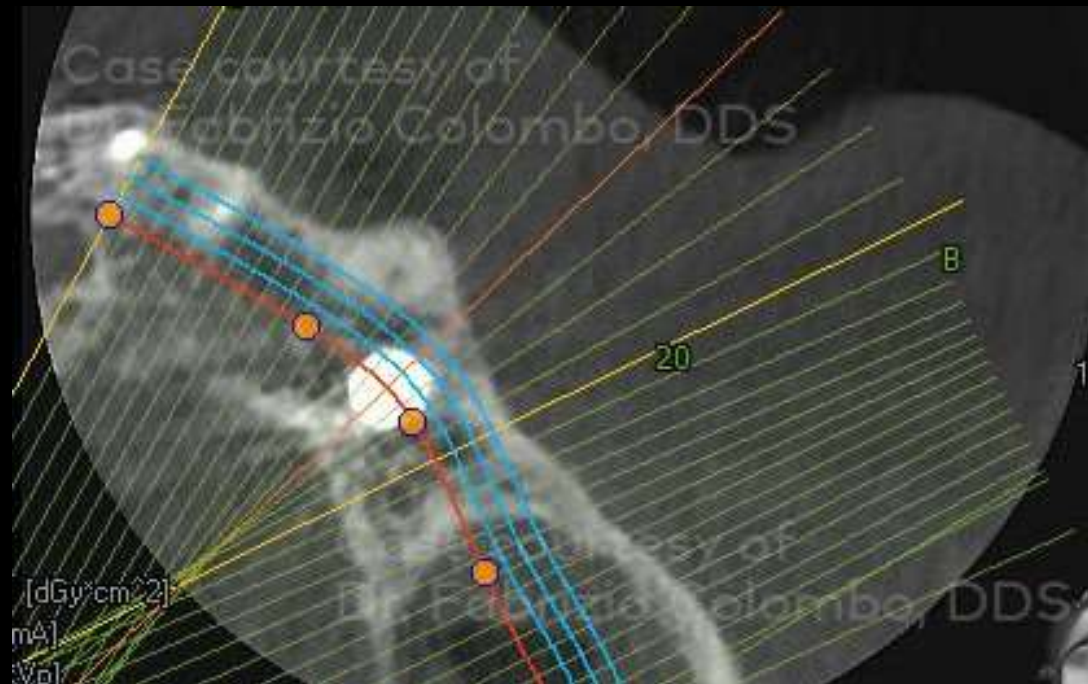
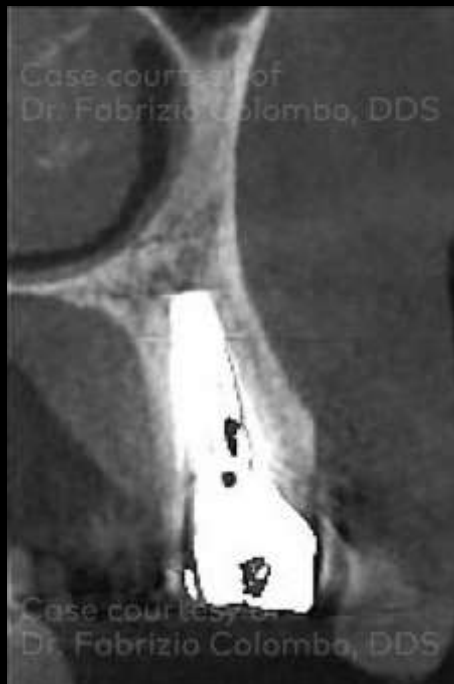Treatment planning

Surgical procedure

Restorative procedure

Outcome

Immediate loading of post extractive single tooth in esthetic zone with simultaneous GBR



CBCT 7 months after the implant placement.

Case courtesy of Dr. Fabrizio Colombo, DDS



GMT86716 GB 2309 © Nobel Biocare Services AG, 2023. All rights reserved. Distributed by: Nobel Biocare. Nobel Biocare, the Nobel Biocare logotype and all other trademarks are, if nothing else is stated or is evident from the context in a certain case, trademarks of Nobel Biocare. Please refer to nobelbiocare.com/trademarks for more information. Product images are not necessarily to scale. All product images are for illustration purposes only and may not be an exact representation of the product. Please contact the local Nobel Biocare sales office for current product assortment and availability. Disclaimer: For prescription use only. Caution: Federal (United States) law or the law in your jurisdiction may restrict this device to sale by or on the order of a licensed clinician, medical professional or physician. See Instructions For Use for full prescribing information, including indications, contraindications, warnings and precautions. OCS-B (Nibe Co., Ltd.) is distributed as creos™ xenogain since September 2016. Legal Manufacturer: Nibe Co., Ltd. Iwol electricity-electronic Agro-industrial Complex, 116 Bamdi-gil, Iwol-myeon, Jincheon-gun, Chungcheongbuk-do, 27816 Korea. Nobel Biocare does not take any liability for any injury or damage to any person or property arising from the use of this clinical case. This clinical case is not intended to recommend any measures, techniques, procedures or products, or give advice, and is not a substitute for medical training or your own clinical judgement as a healthcare professional. Viewers should never disregard professional medical advice or delay seeking medical treatment because of something they have seen in this clinical case. Full procedure is not shown. Certain sequences have been cut.