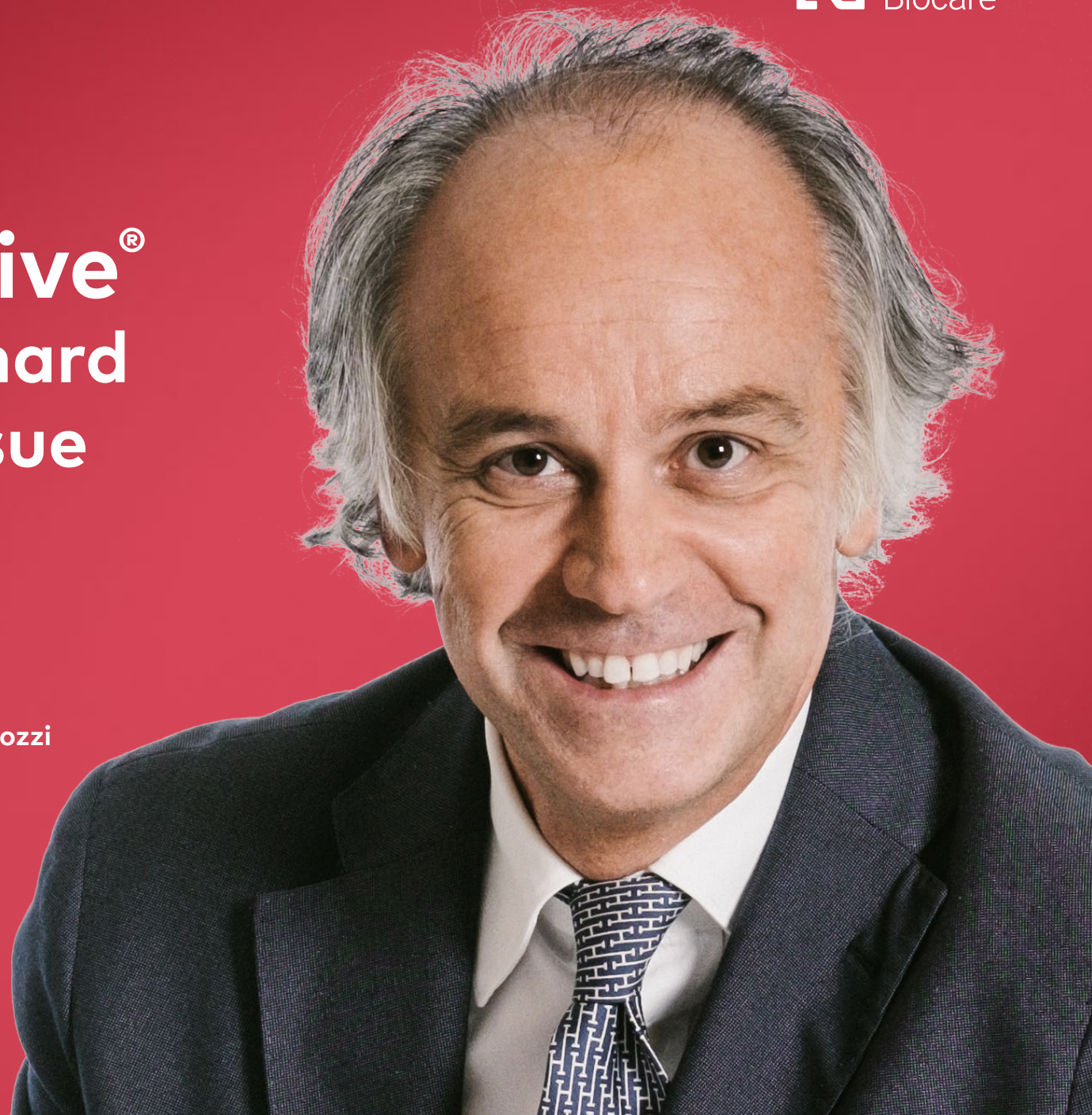

CLINICAL CASE



NobelActive[®] supporting hard and soft tissue long-term

Alessandro Pozzi
Italy





Alessandro Pozzi

Patient

48 years old male patient with good medical condition

Clinical situation

Failing porcelain-fused-to-metal fixed dental prostheses on tooth numbers 24 and 25

Surgical solution

Immediate placement of a NobelActive RP 4.3x13 mm implant after extraction of tooth 24 and root canal treatment of tooth 25 socket

Socket augmentation and autogenous soft tissue grafting to close the socket and increase the amount of soft tissue at the recipient site

Restorative solution

Provisionalization of implant with a screw-retained restoration.

Final lithium disilicate crown

Surgery date(s)

10/01/2008

Total treatment time

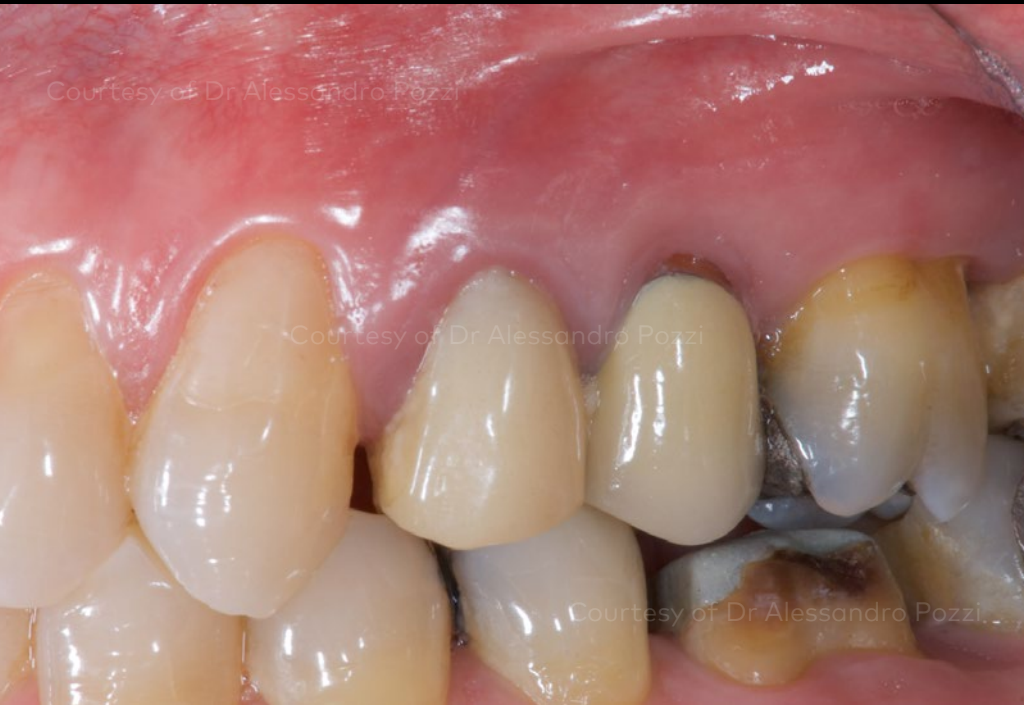6 months

"After have been using NobelActive since 2007 I'm still wondered by its excellent mechanical and biologic properties and outcomes. The implant primary stability is easy to achieve even in fresh extraction socket with poor quality bone and the immediate placement and provisionalization of single teeth are more predictable and safe for the patient. After 10-year in the function, the bone level around the NobelActive implant still exceeds my expectations and is not unusual to appreciate a bone overgrowth onto the NobelActive platform over time. NobelActive is my choice when I want to deliver immediate function and esthetic, shorten the overall treatment time and guarantee a long-lasting success."

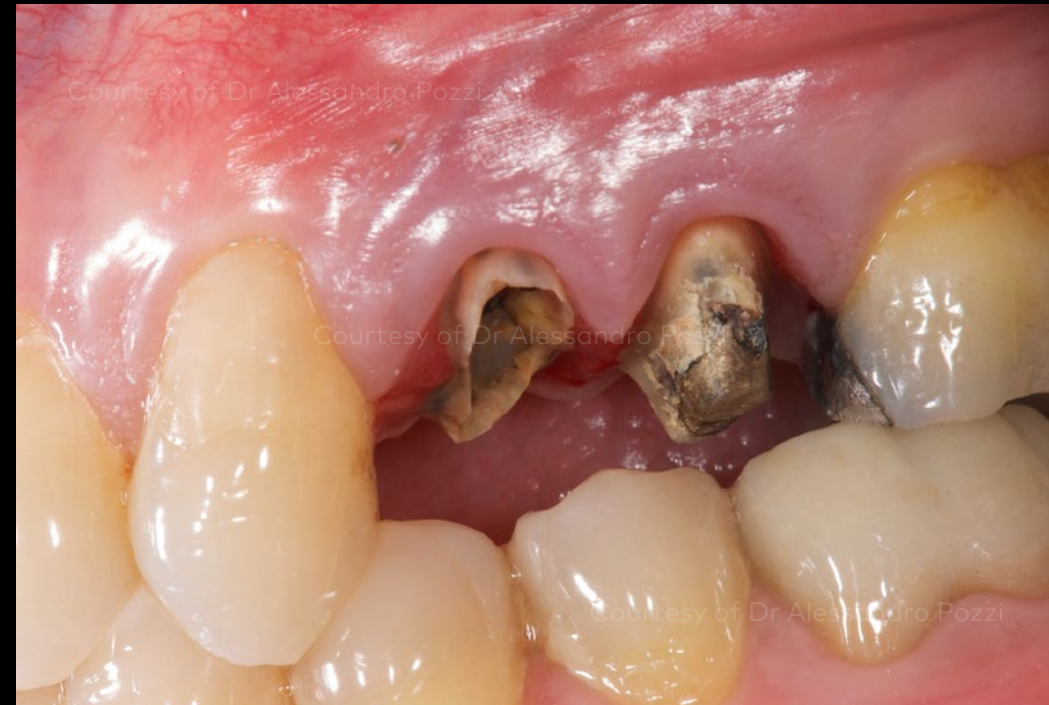Initial clinical situation

Surgical procedure

Outcome



Failed Porcelain Fused to Metal Fixed Dental Prostheses on tooth number 24 and 25.

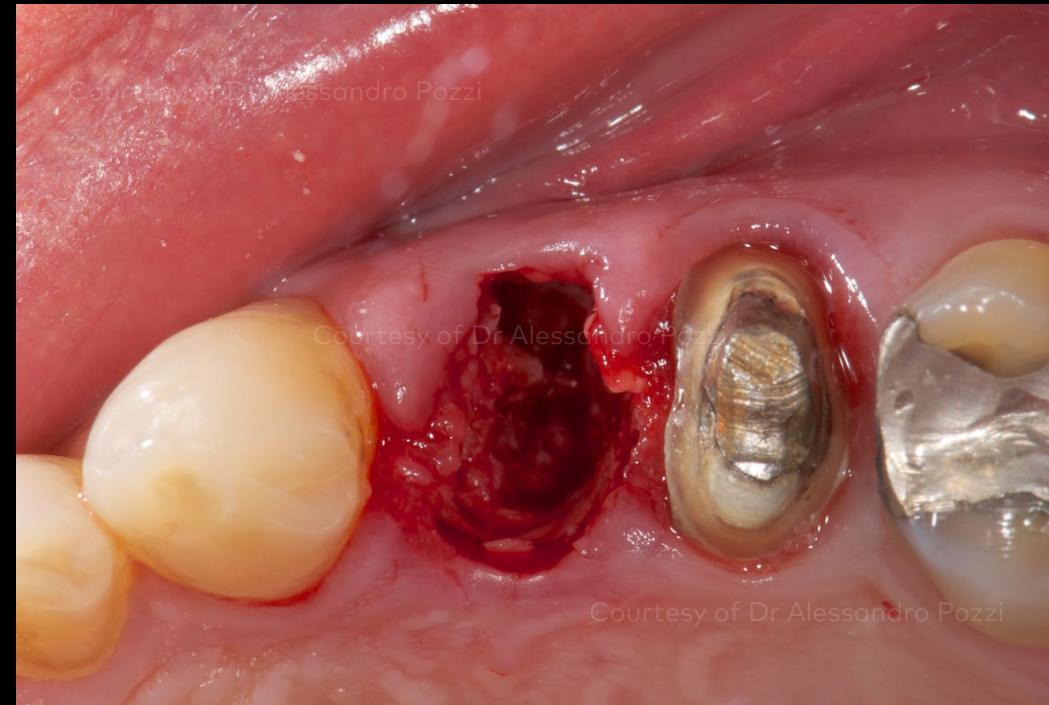
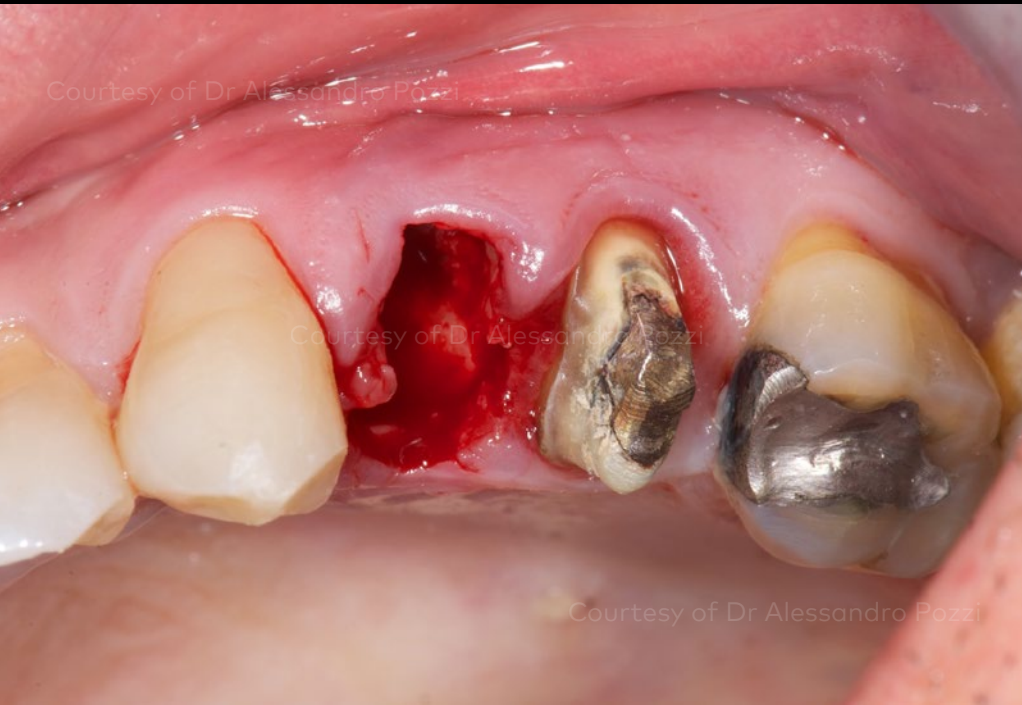

After the removal of the crowns. The clinical examinations showed periapical infection and root fracture at tooth 24; and gingival inflammation, bleeding on probing and 4 mm of periodontal probing depth on both teeth.

Initial clinical situation

Surgical procedure

Outcome



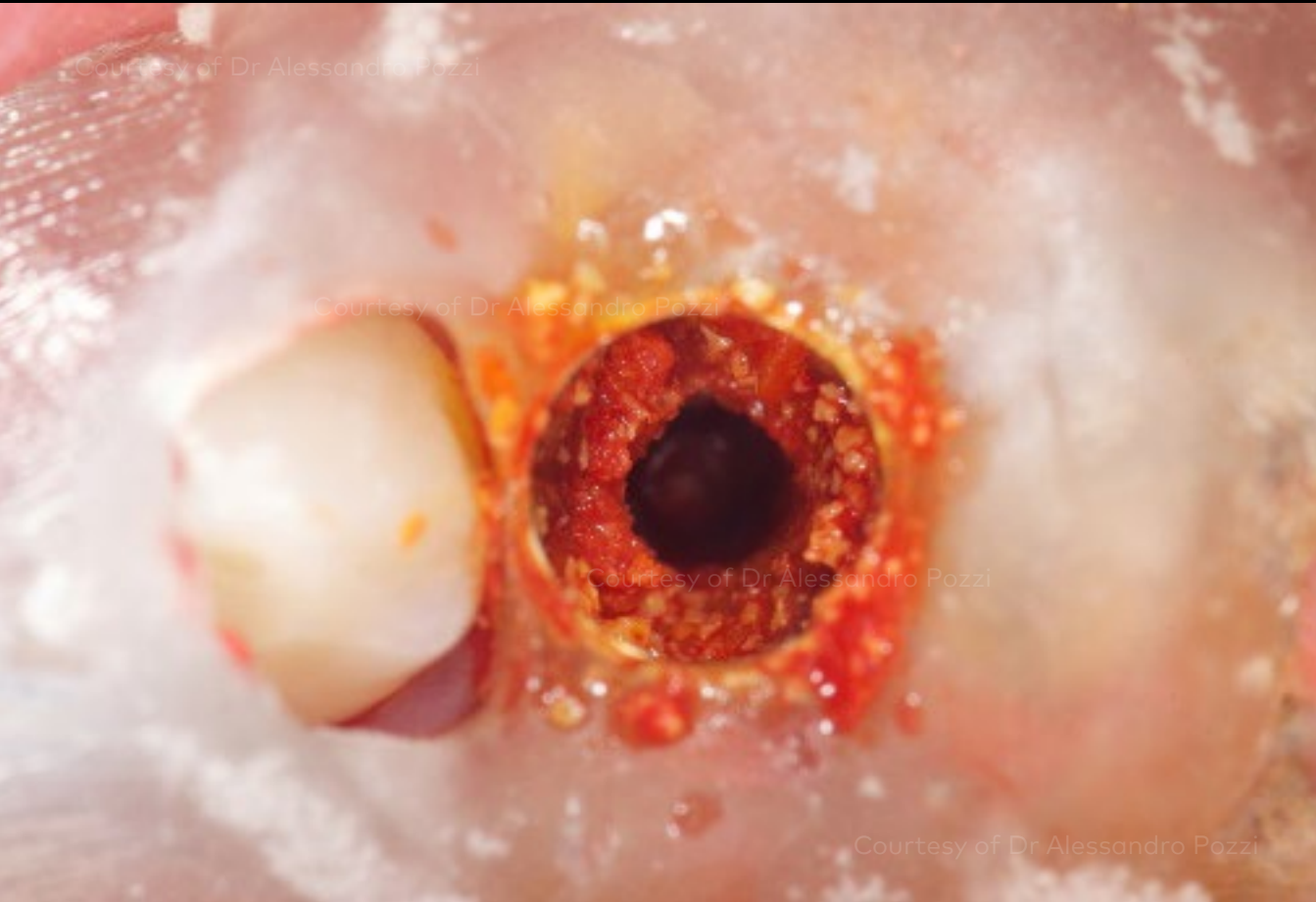
A minimally invasive tooth extraction without elevating a gingival flap was performed to maintain the integrity of the buccal plate and proximal bone peaks.

The height of residual bone after mechanical and chemical debridement and disinfection with antibiotic solution (Rifampicin) was 7 mm.

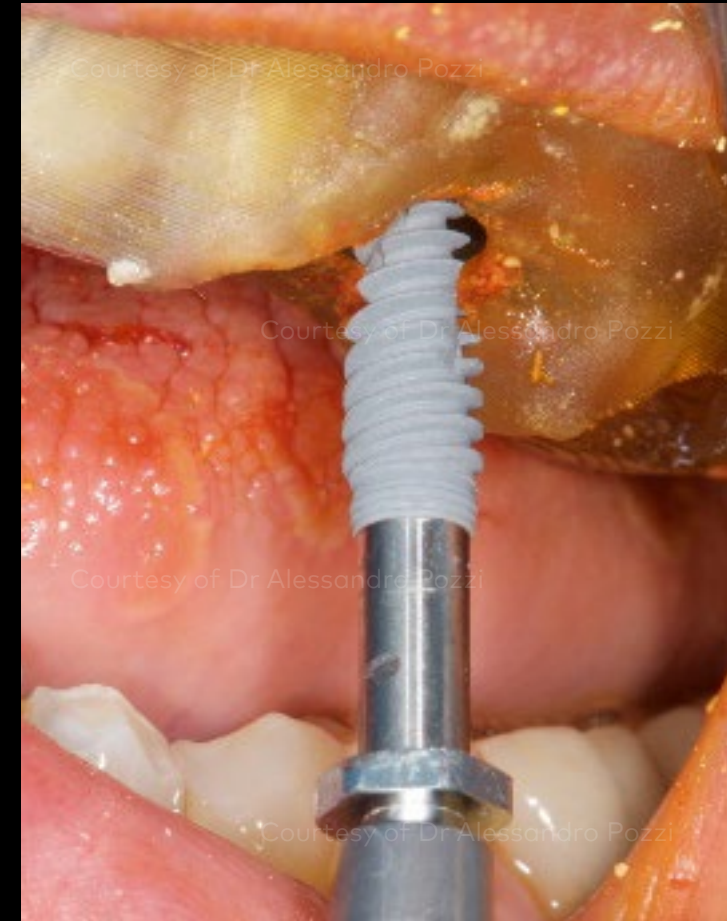Initial clinical situation

Surgical procedure

Outcome



Intraoperative view through the surgical template

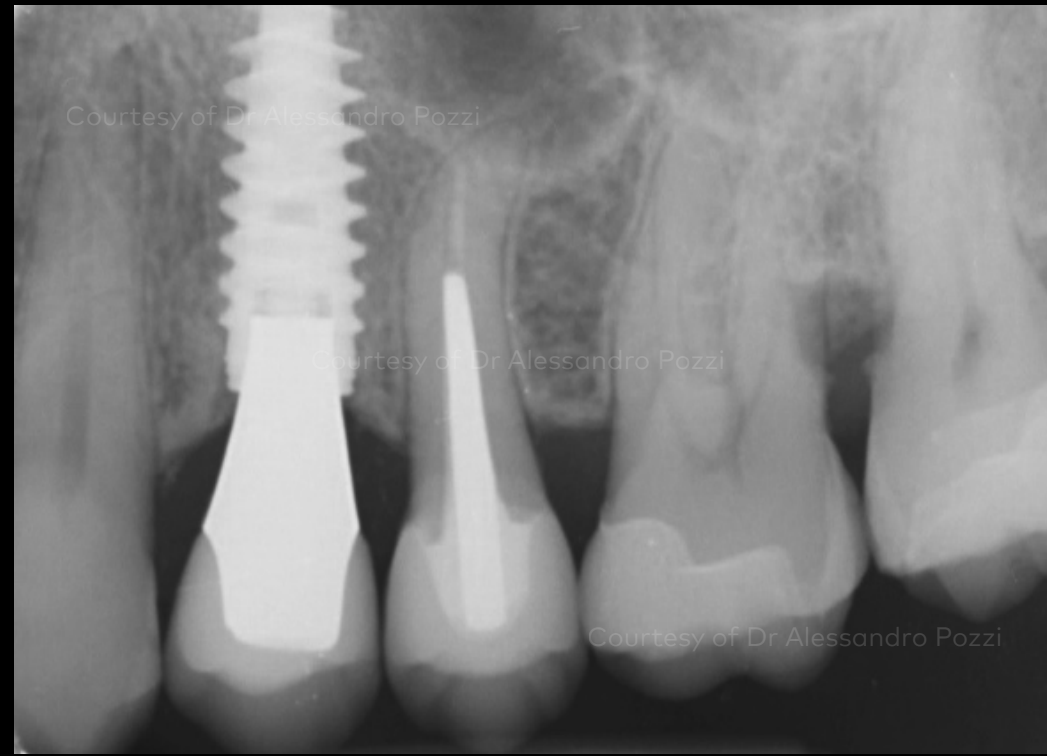
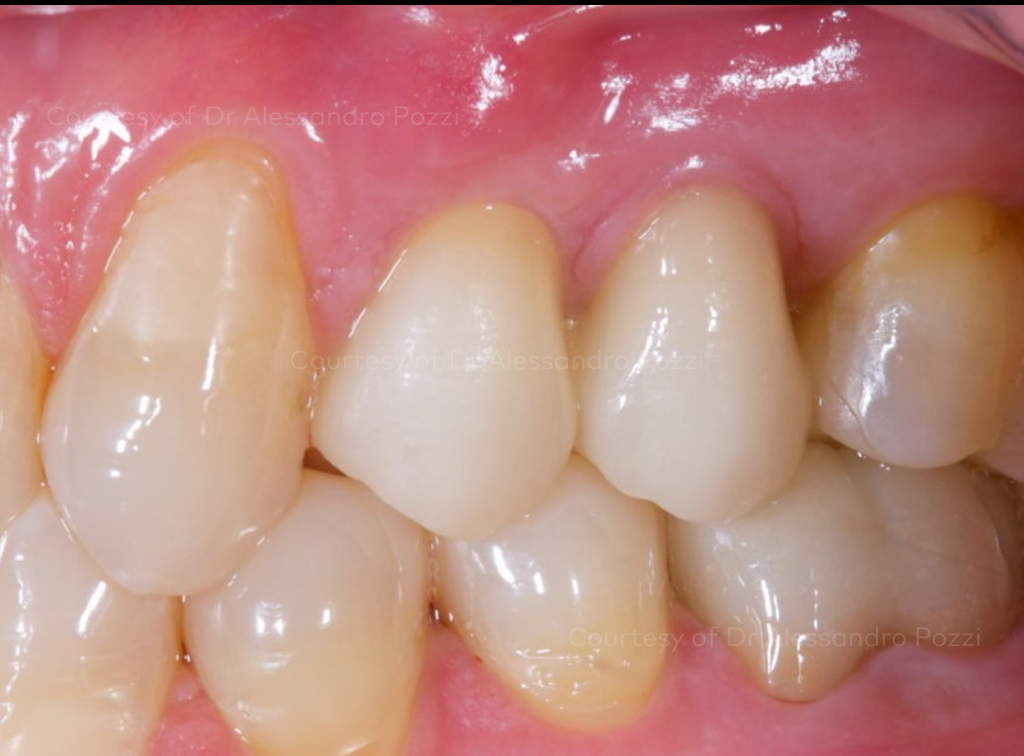

Intraoperative view during implant insertion

Initial clinical situation

Surgical procedure

Outcome



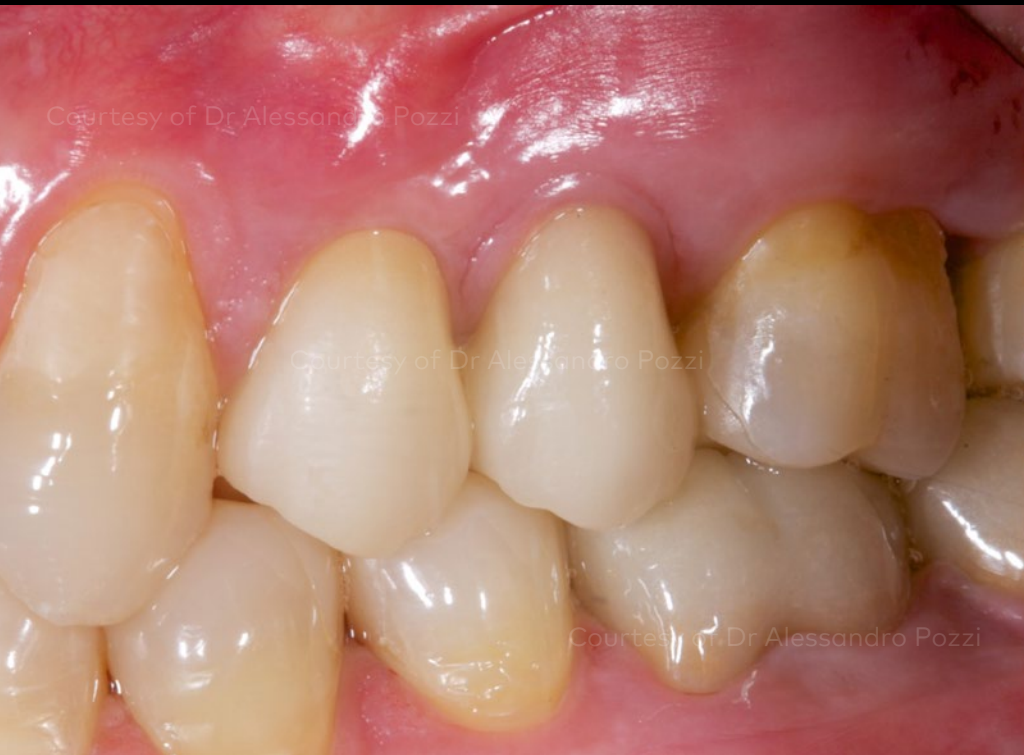Clinical outcome with NobelActive at 3-year follow-up, showing healthy papilla.

Radiological outcome with NobelActive at 3-year follow-up, showing stable bone.

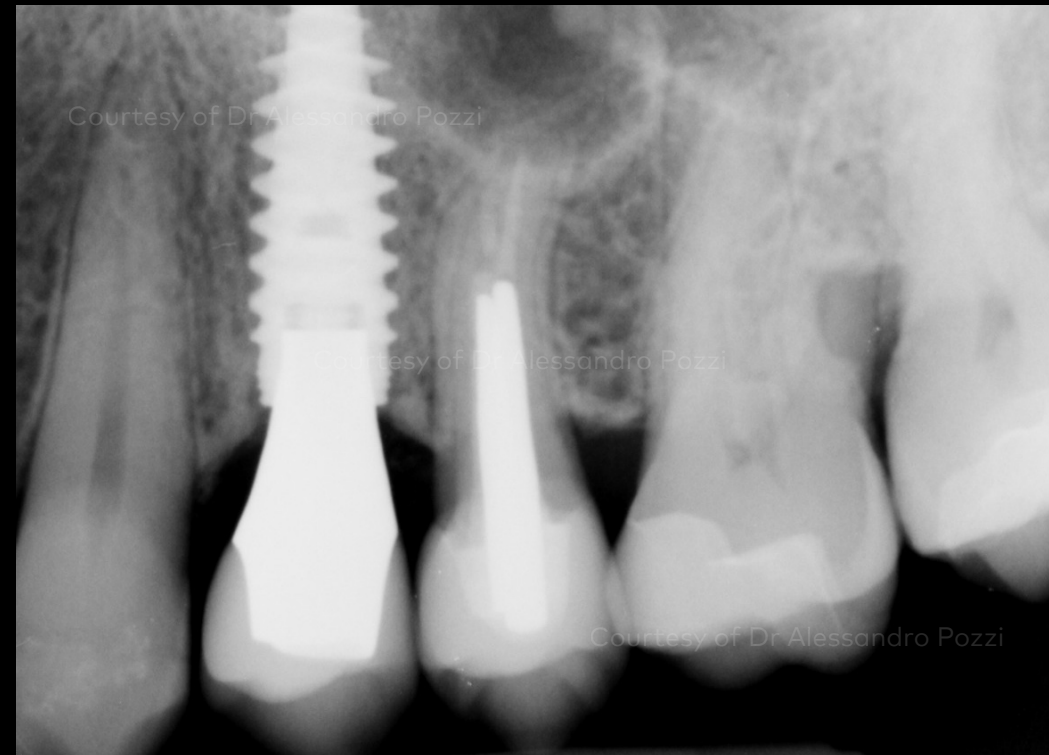
Initial clinical situation

Surgical procedure

Outcome



Clinical outcome with NobelActive at 5-year follow-up, showing healthy papilla.

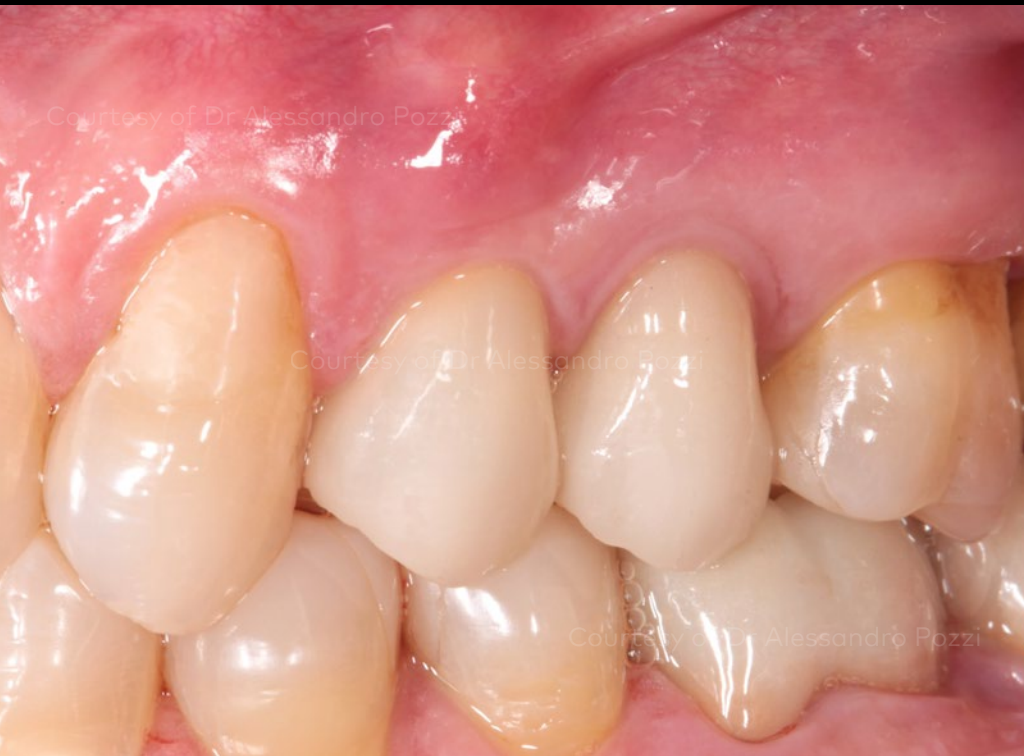

Radiological outcome with NobelActive at 5-year follow-up, showing stable bone.

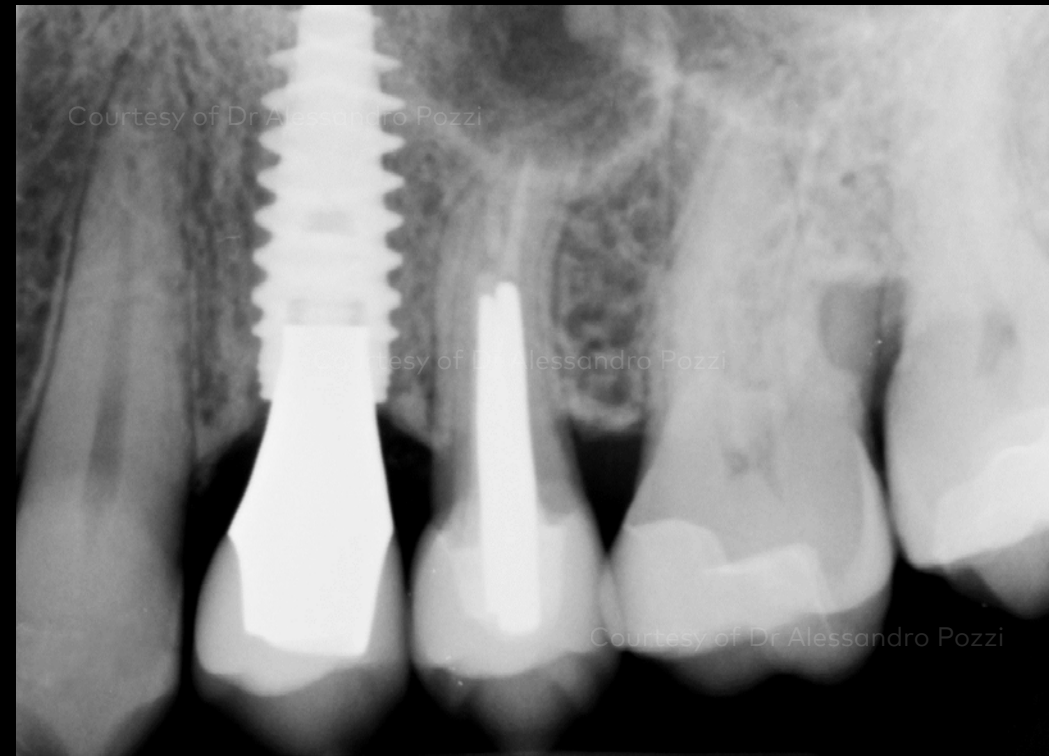
Initial clinical situation

Surgical procedure

Outcome



Clinical outcome with NobelActive at 7-year follow-up, showing healthy papilla.

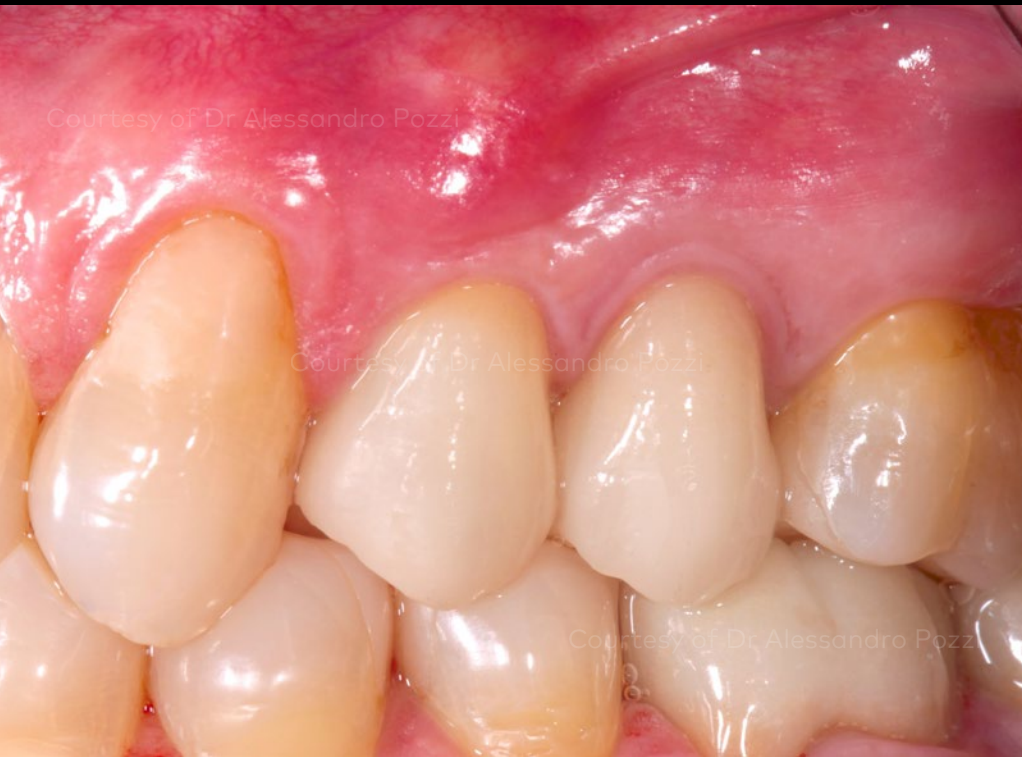

Radiological outcome with NobelActive at 7-year follow-up, showing stable bone.

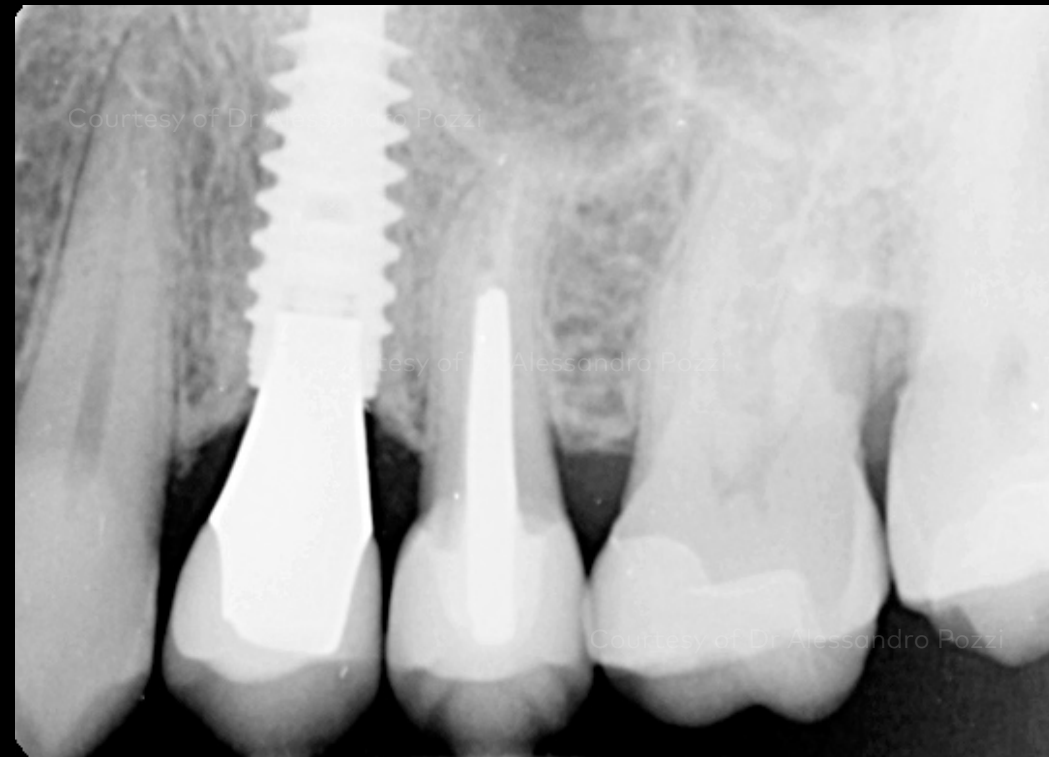
Initial clinical situation

Surgical procedure

Outcome



Clinical outcome with NobelActive at 10-year follow-up. Papilla-index improved over time.

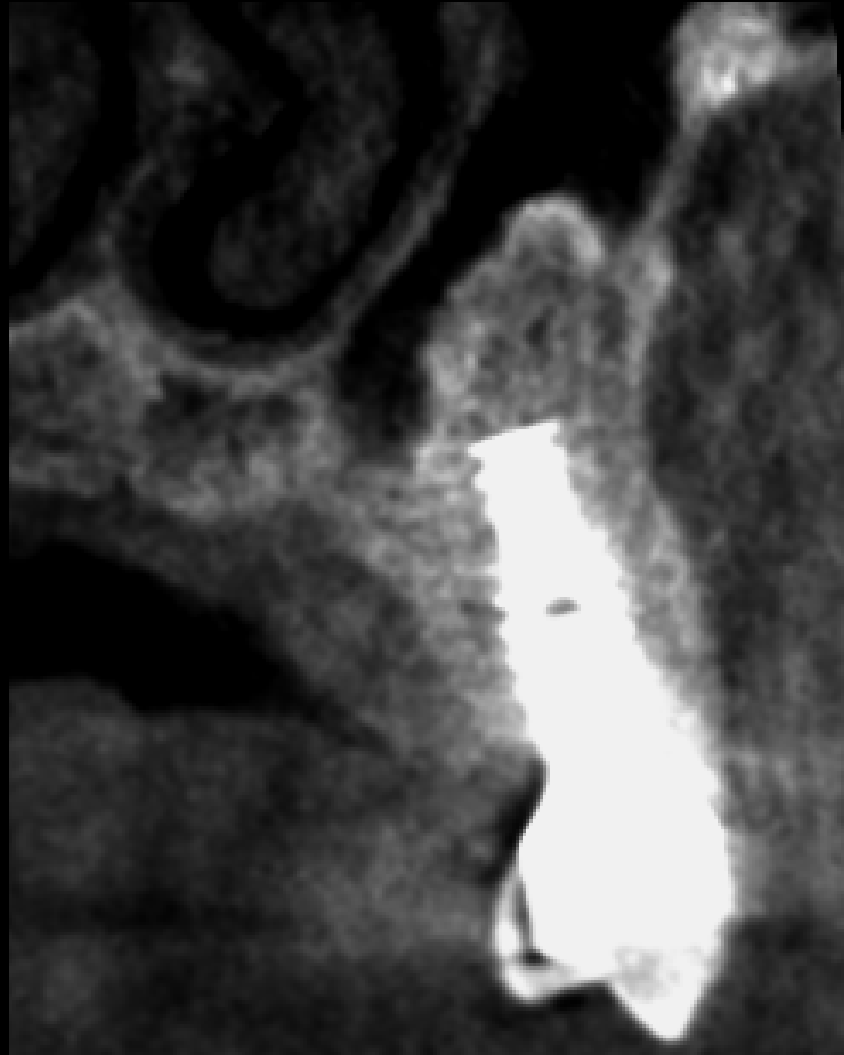

Radiological outcome with NobelActive at 10-year follow-up, showing stable bone.

**Initial clinical
situation**

**Surgical
procedure**

Outcome



Cone beam computed tomography image obtained 10 years after implant insertion, showing bone growth onto the implant platform.

Case courtesy of Dr Alessandro Pozzi

